

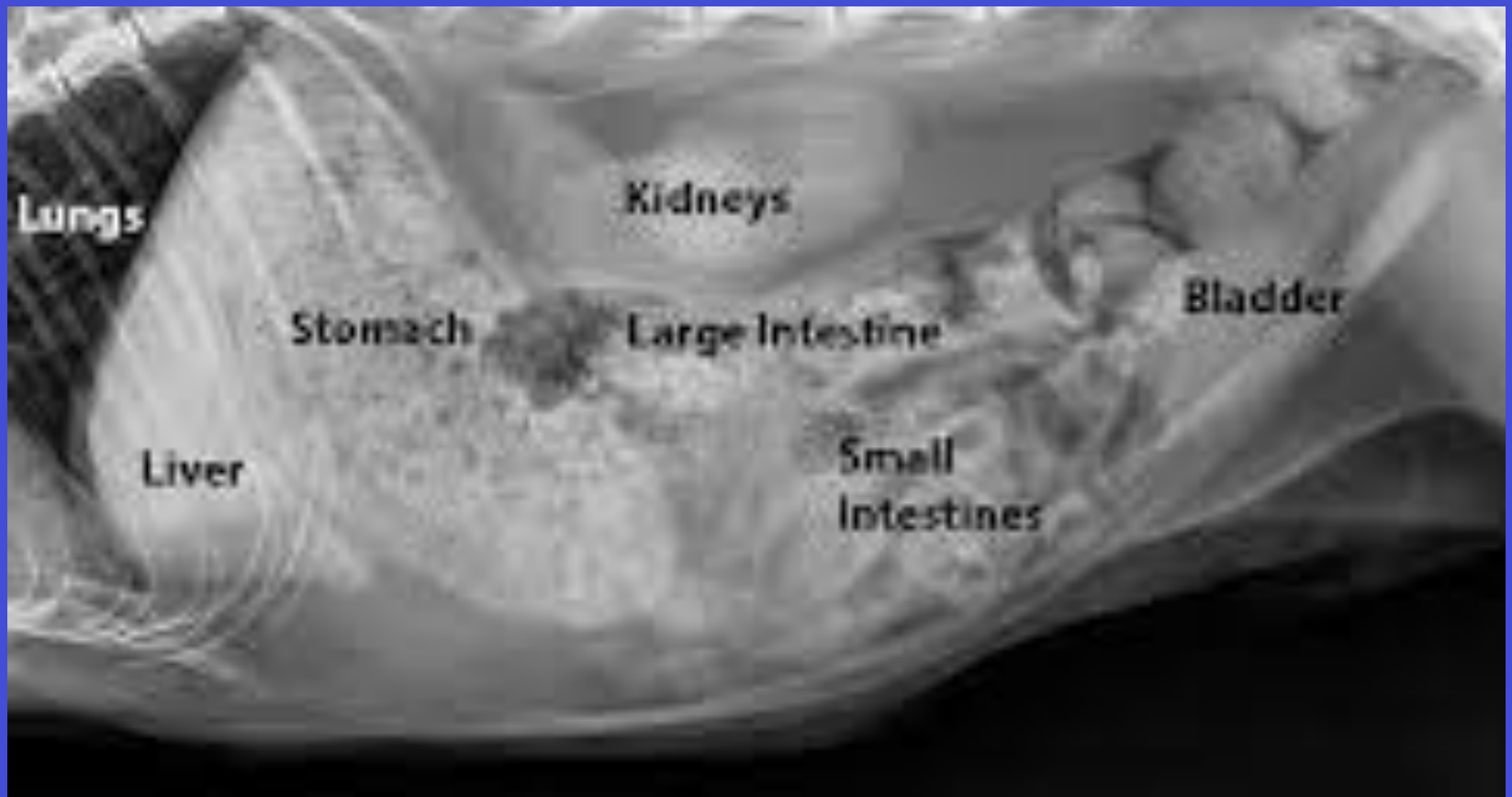

Small Animal Radiology

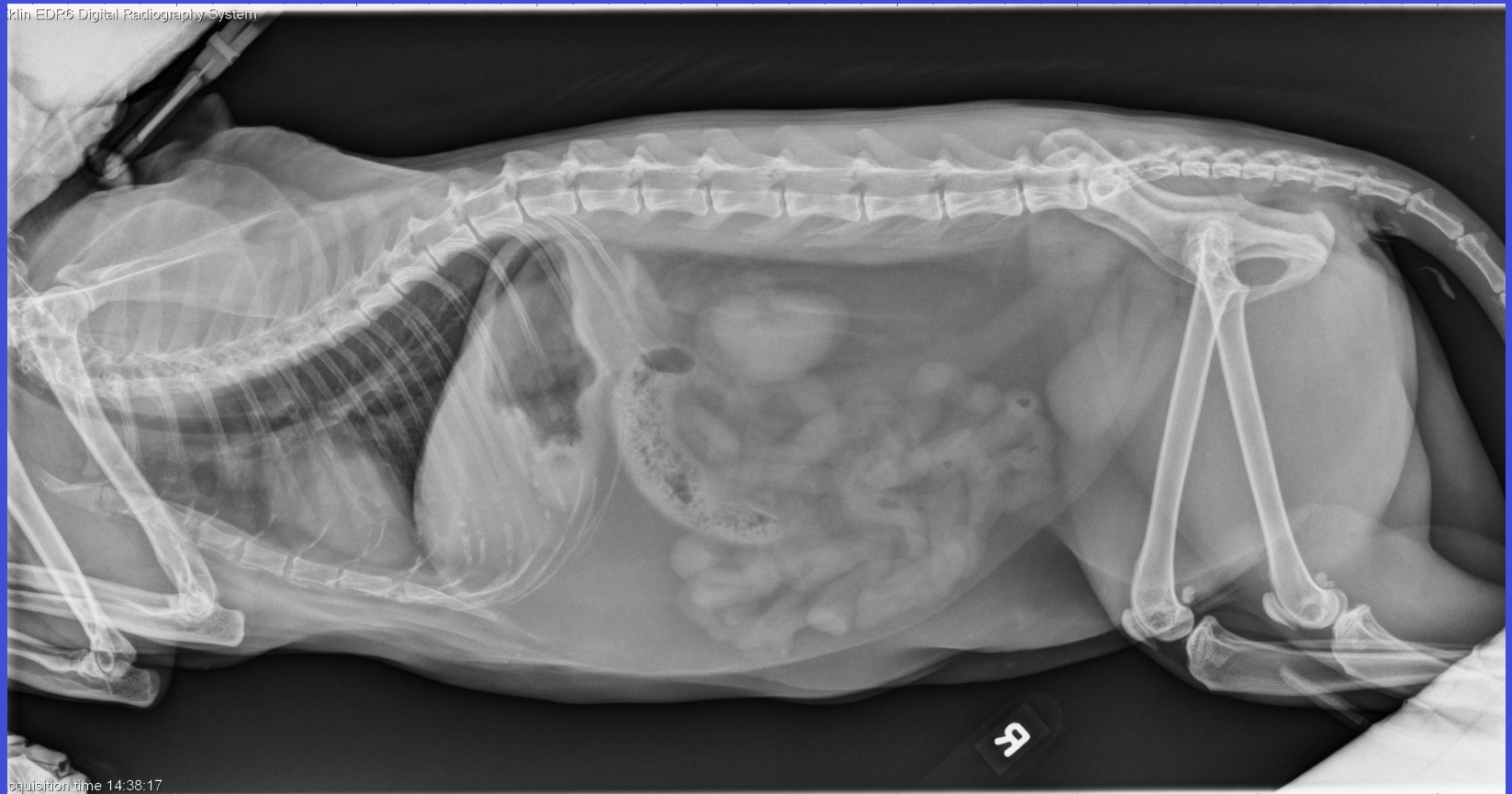
Gastrointestinal

Dr. Ed Neufeld B.A. M.Div. D.V.M.

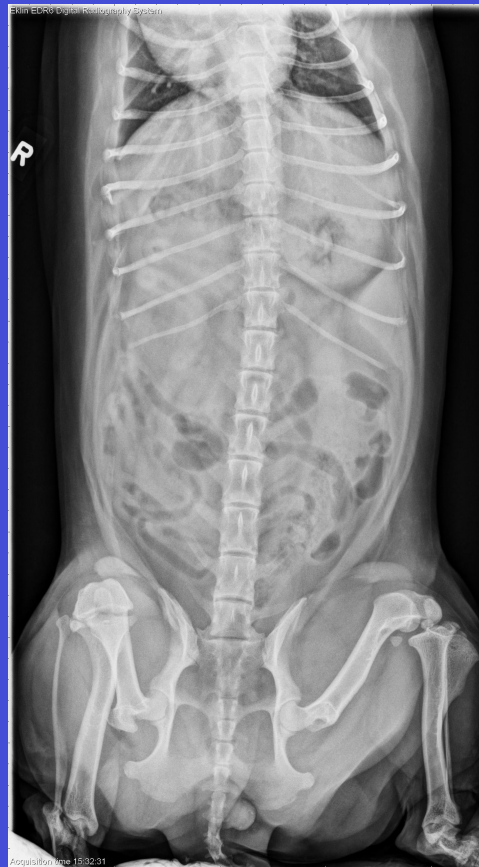Abdominal X-ray Normal Canine



Normal Abdominal X-ray



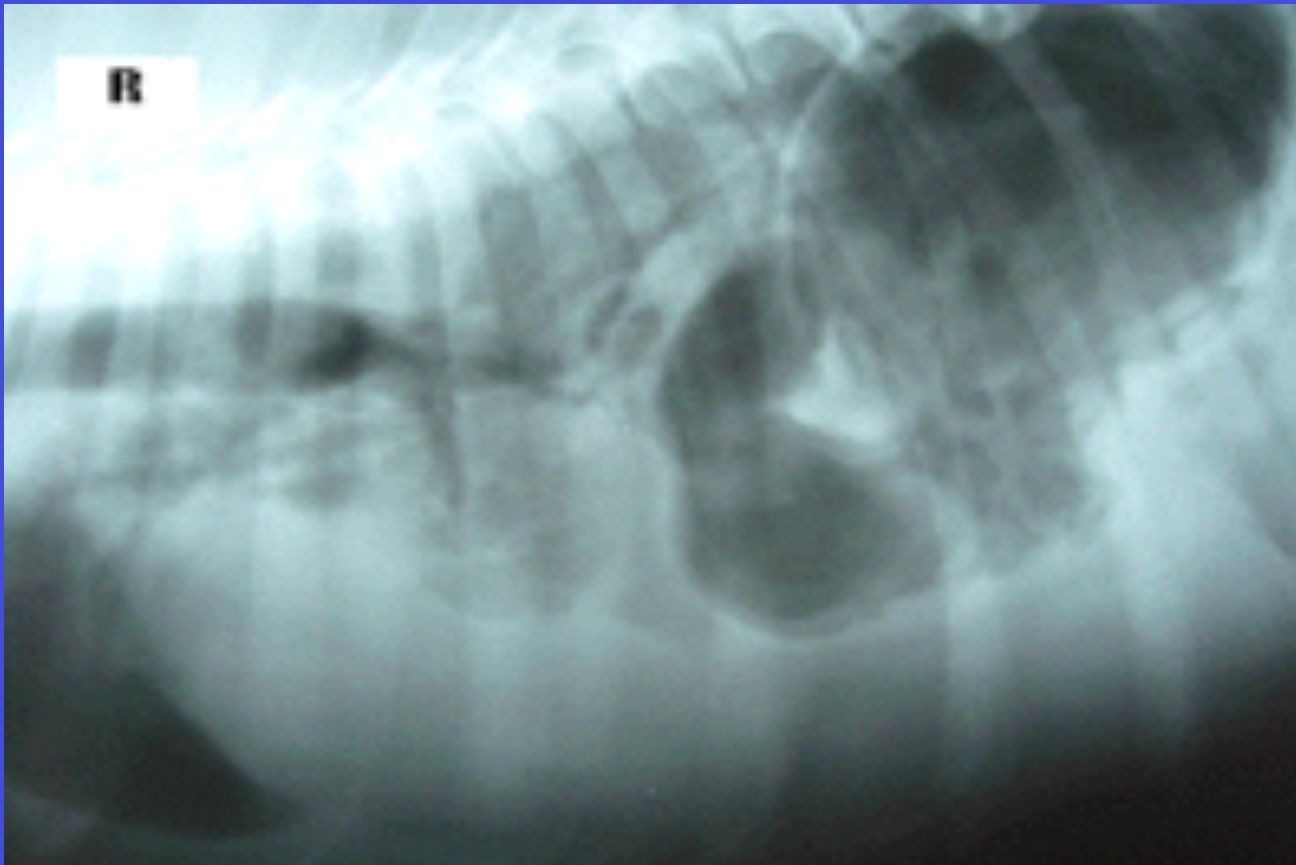
Normal Canine V/D



Case #1

- Spike was hit by a car 1 hour ago and is brought to your clinic in respiratory distress. You decide to do an thoracic radiograph.

Lateral Thoracic X-Ray



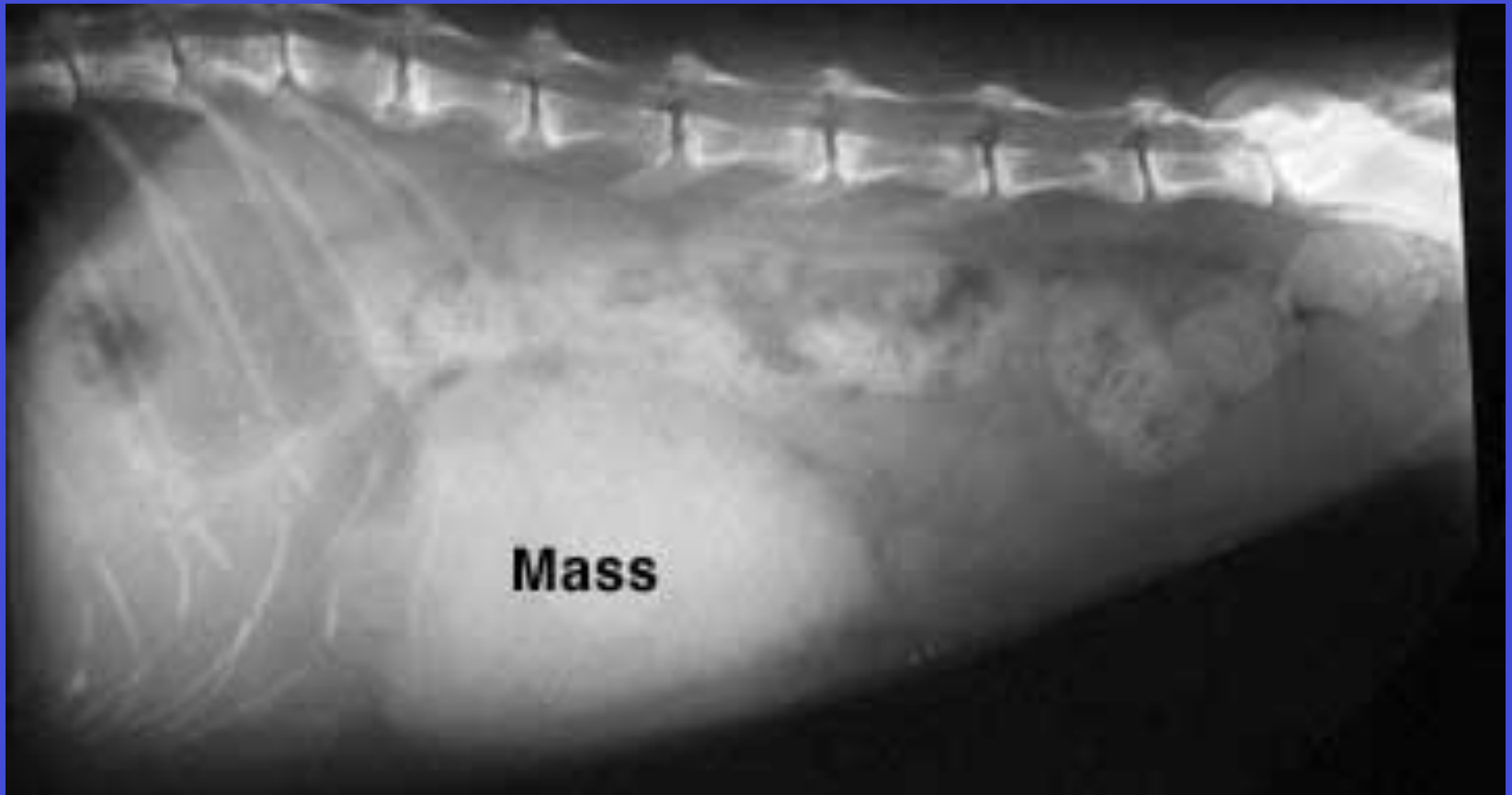
Diaphragmatic Hernia



Case # 2

- Stella has pale mucous membranes and is very lethargic. She seemed to be fine yesterday. You do an abdominocentesis and withdraw 10 mls of blood from her abdomen.
- You decide to do an abdominal x -ray.

Abdominal x-ray – Left Lateral



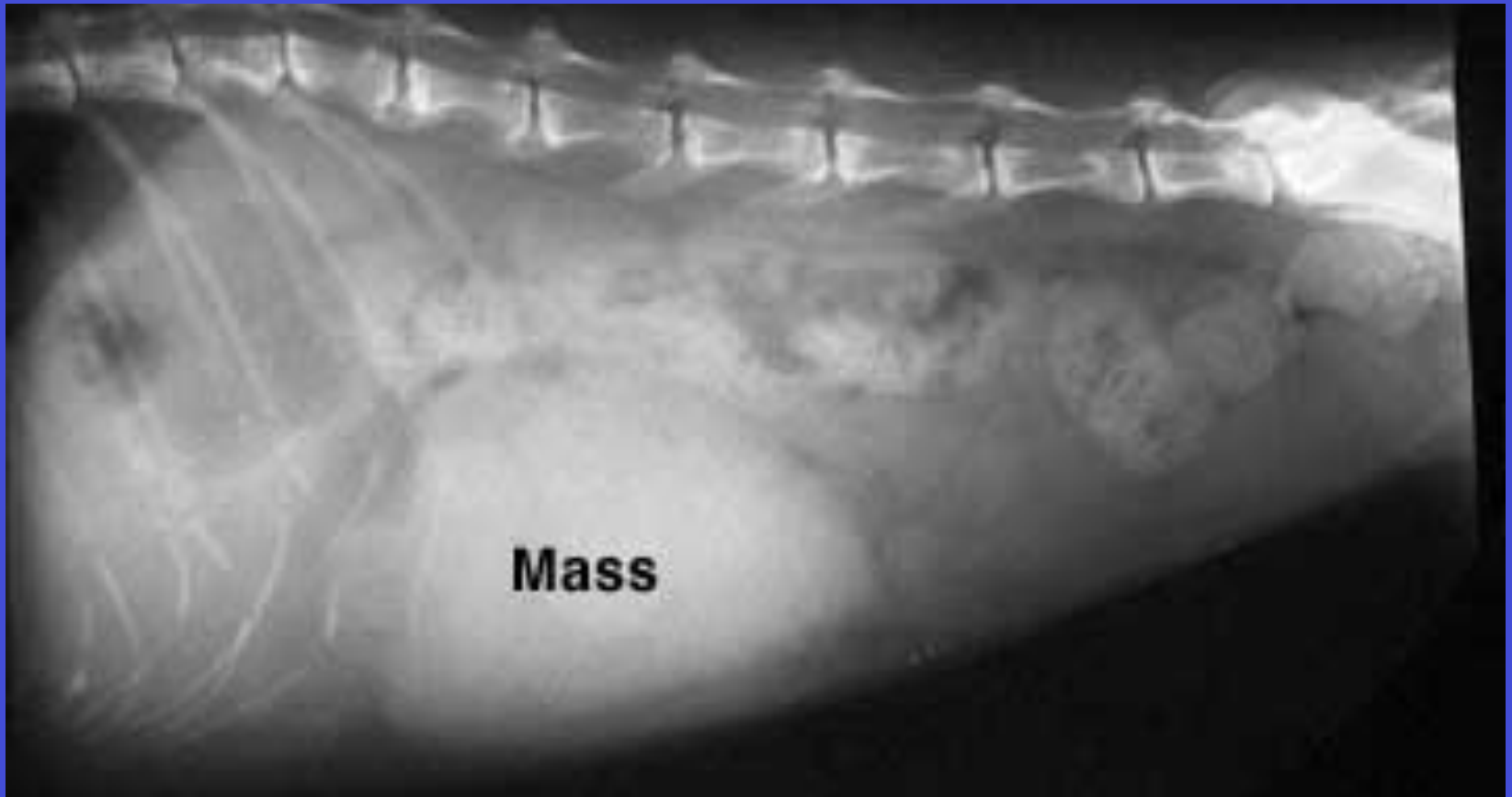
Rule Out Diagnosis for Abdominal Mass

- What are the possible diagnosis?

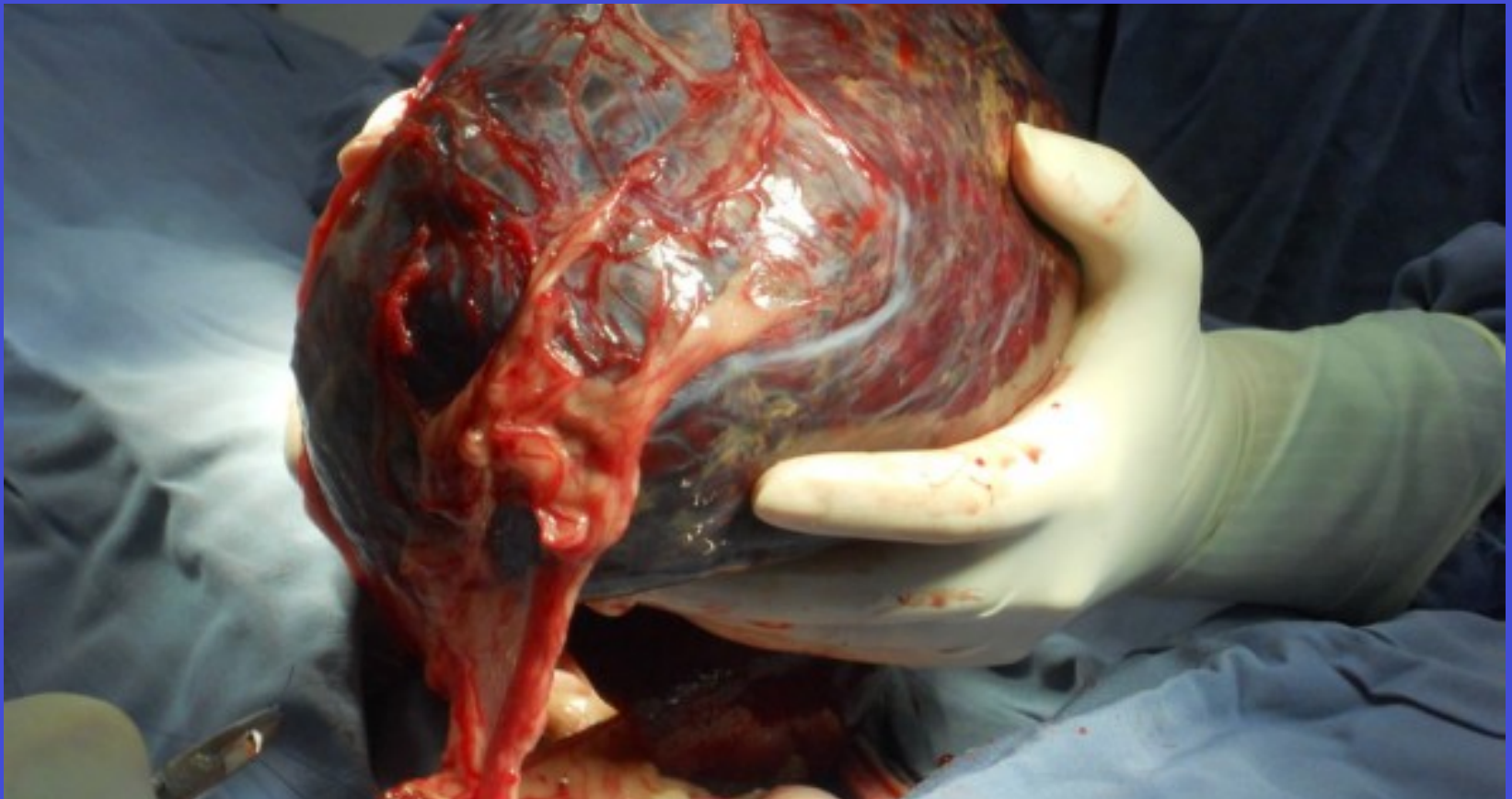
Rule Out Diagnosis of Abdominal Mass

- 1. Splenic Tumor
- 2. Splenic Hematoma

Splenic Tumor



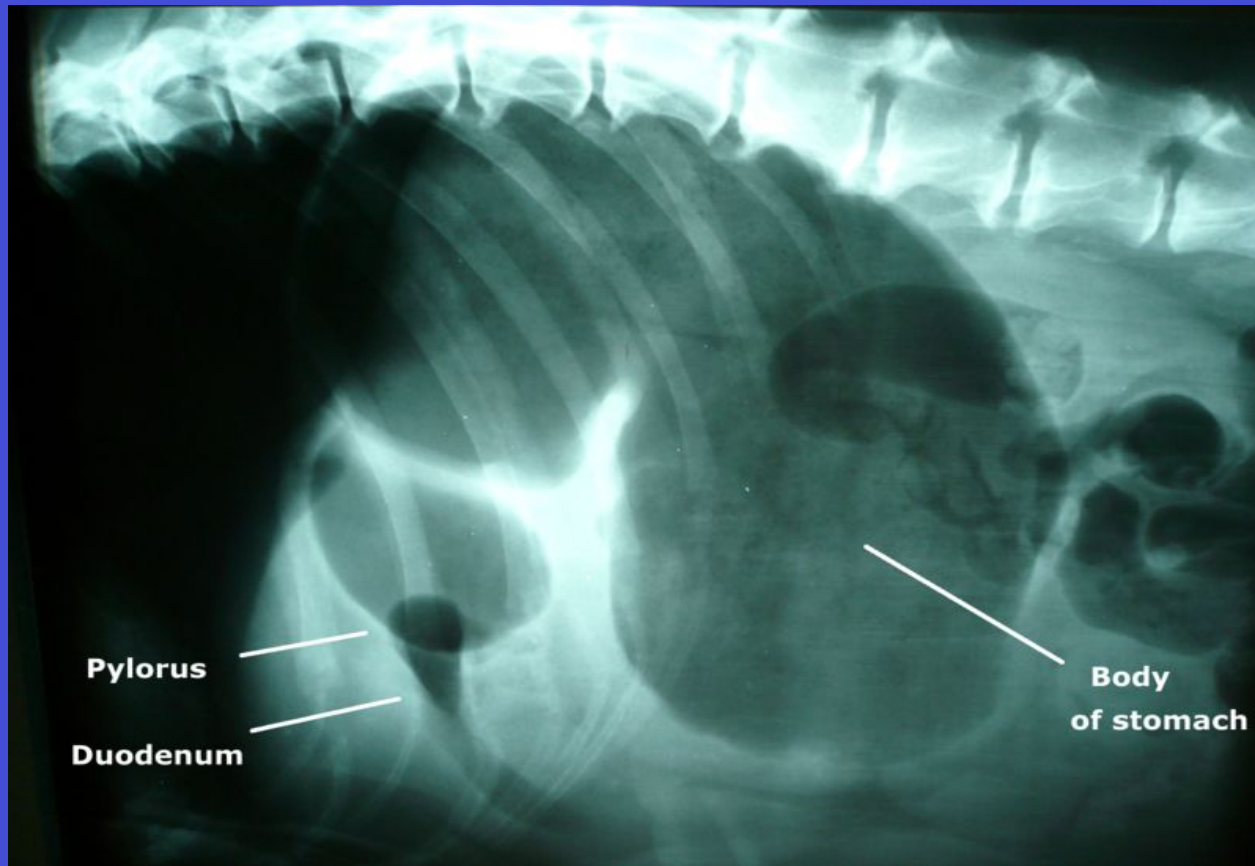
Splenic Hematoma



Case # 3

- Luna is a 20 kg Standard Poodle that begins to retch, salivate and pant after intense exercise. Initially she was very anxious but soon becomes lethargic.
- You decide to do an abdominal radiograph.

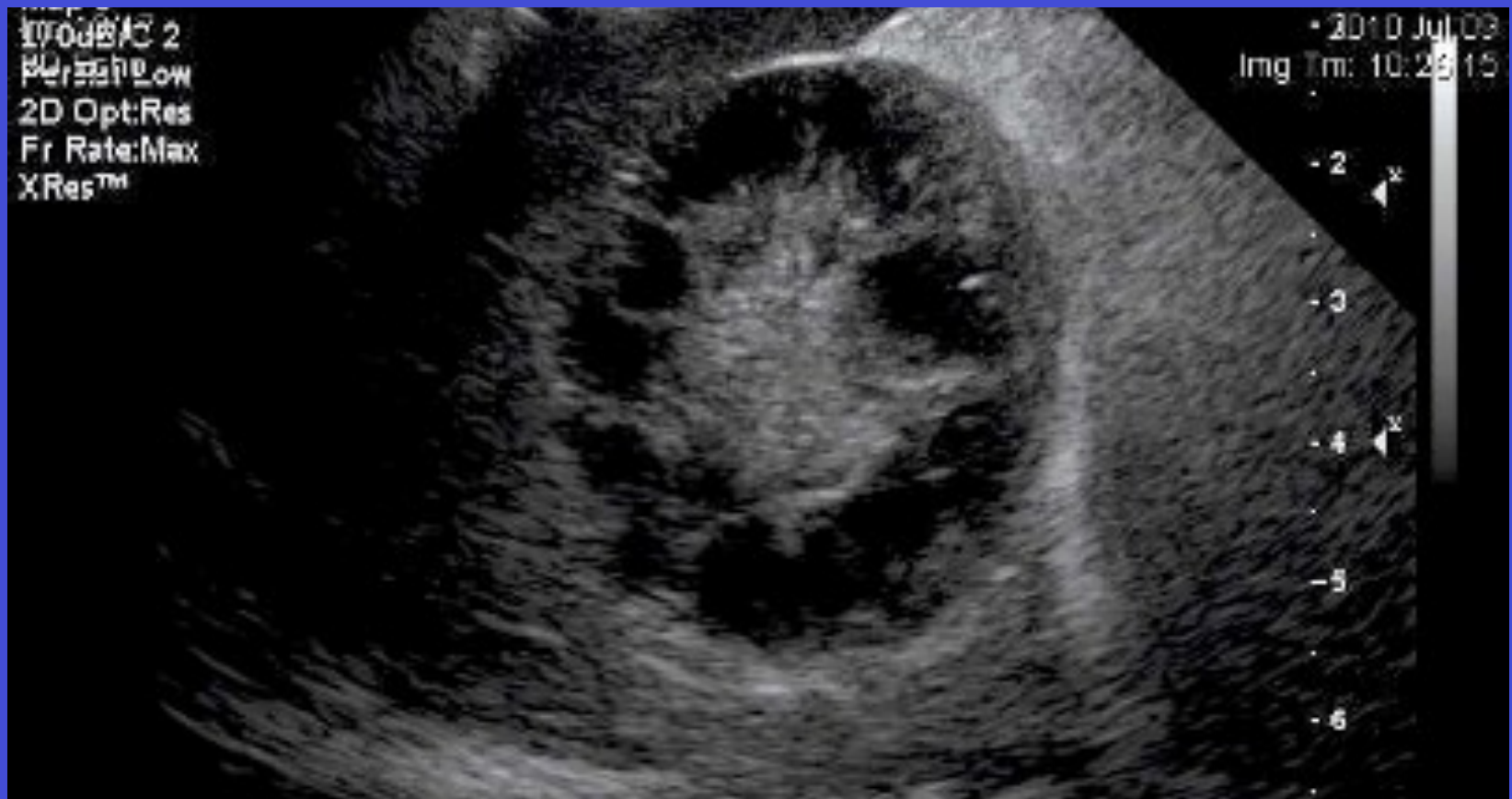Right Lateral Abdominal X-ray



Case # 4

- Rex is a 4 year old Springer Spaniel that has become anorexic and lethargic. During the last few days he vomits occasionally.
- You do serum chemistry and discover his liver enzymes are increased.
- The abdominal radiographs are normal
- What should you do next?

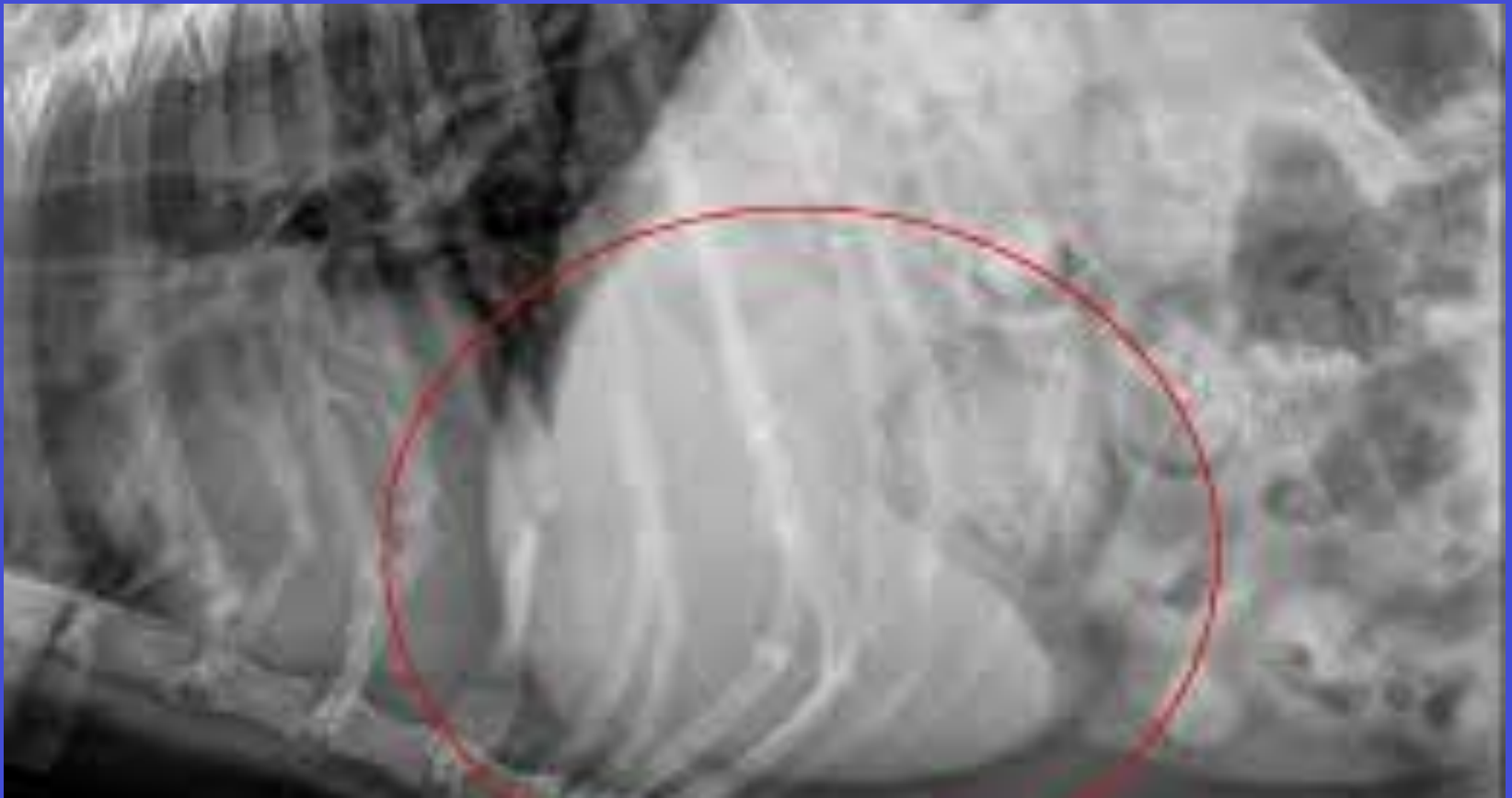
Abdominal Ultrasound



Biliary Mucocele

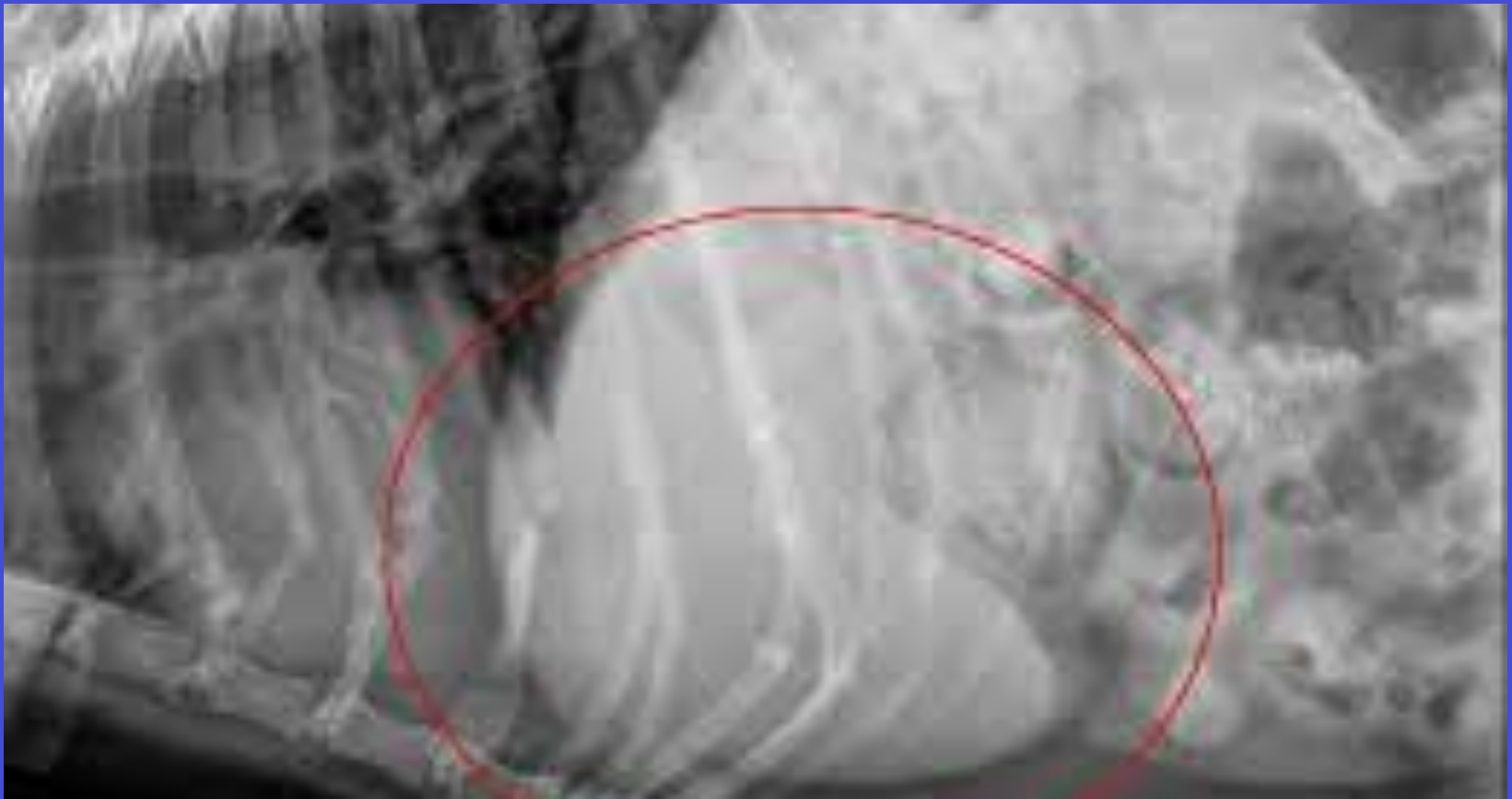


Abdominal x-ray right lateral



Abdominal x-ray right lateral

Hepatomegaly



Case # 5

- Sarah is a 2 year old DSH cat who is anorexic, vomited 4 times this morning, and is 8 % dehydrated.
- You decide to an abdominal x-ray.

Abdominal X-ray Right Lateral

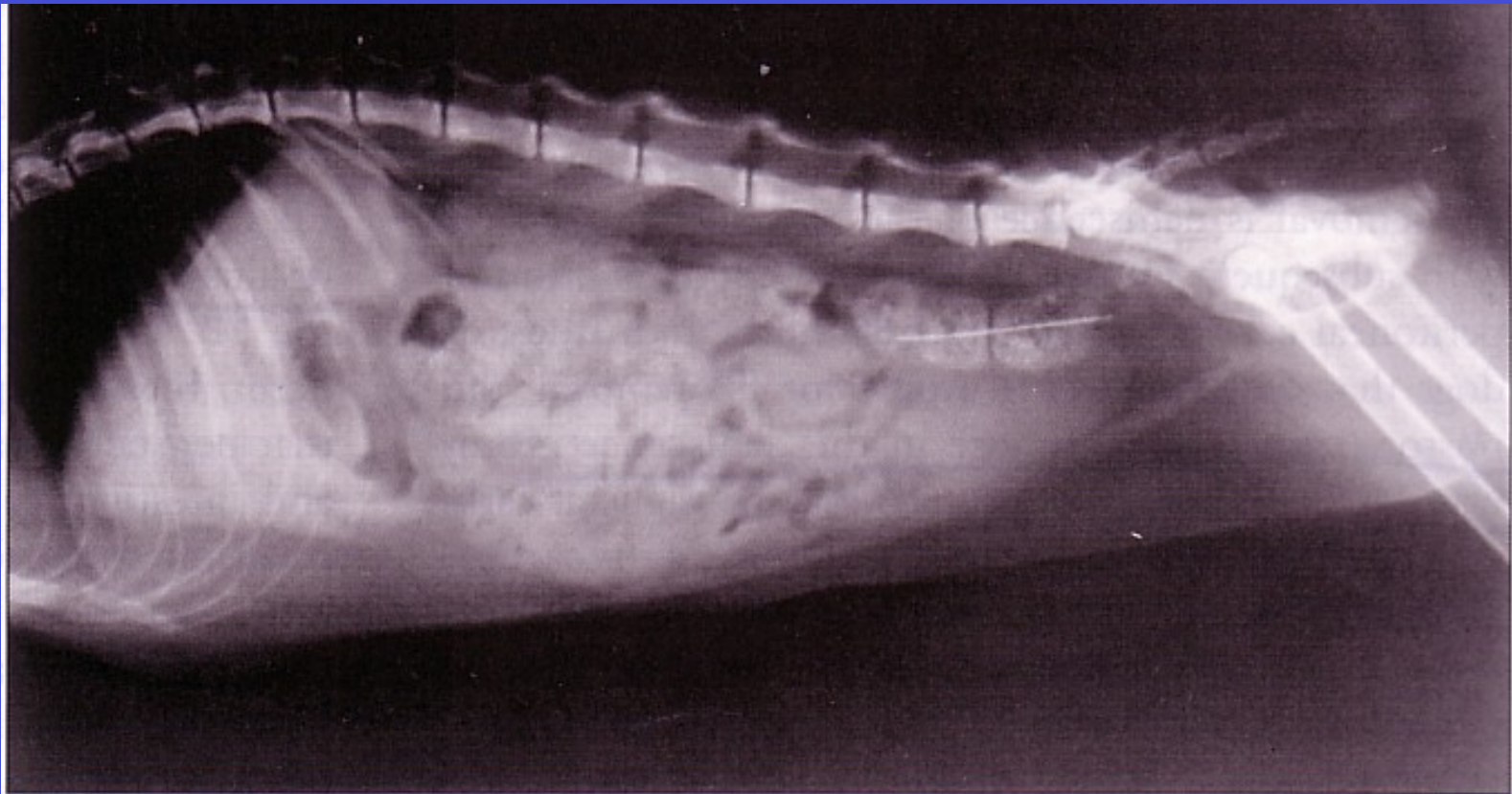


Figure 5. Lateral abdominal radiograph of a cat with intestinal plication and tapered gas.

Linear Foreign Body –

notice the bunching up of the small intestines

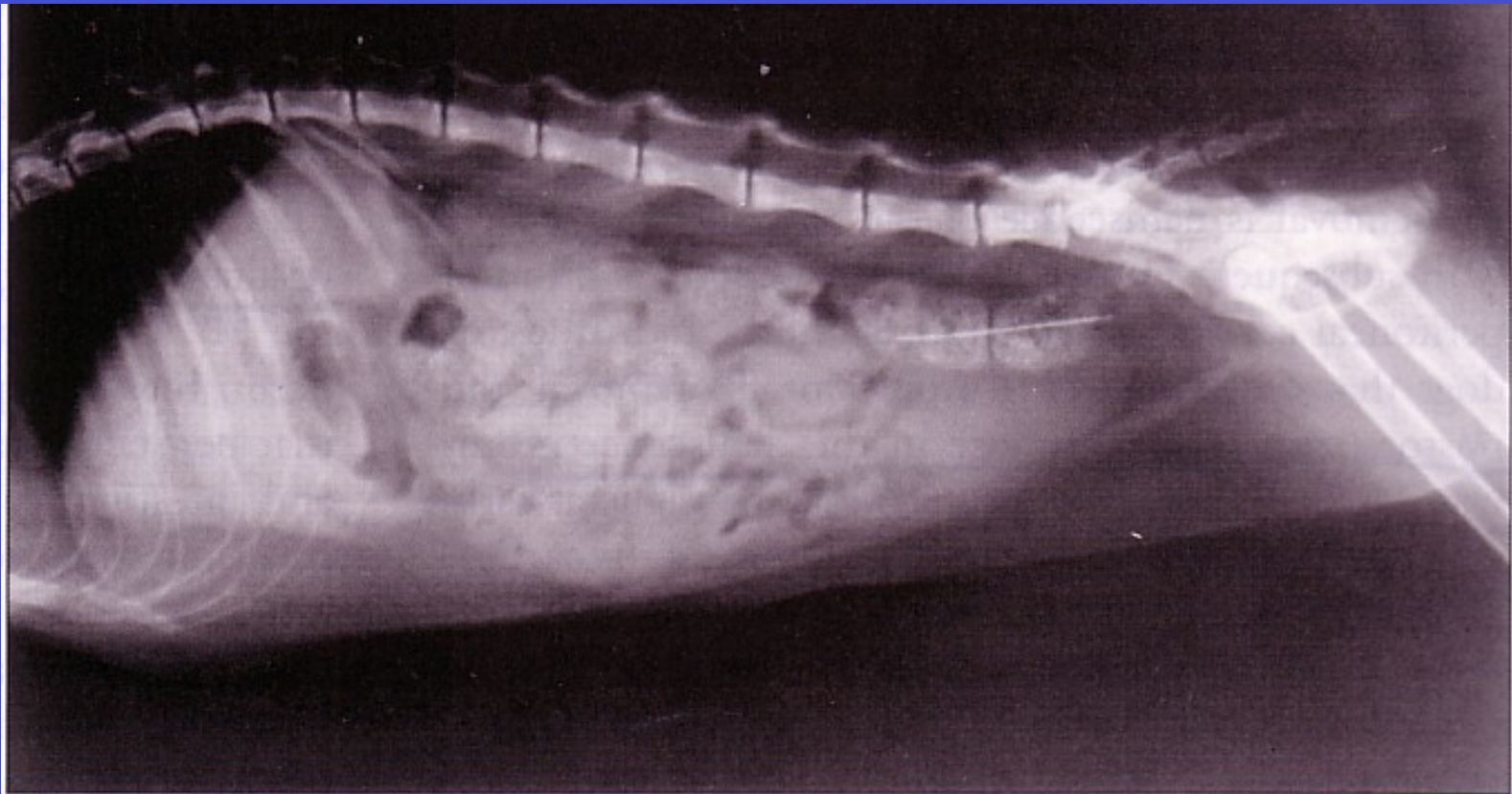
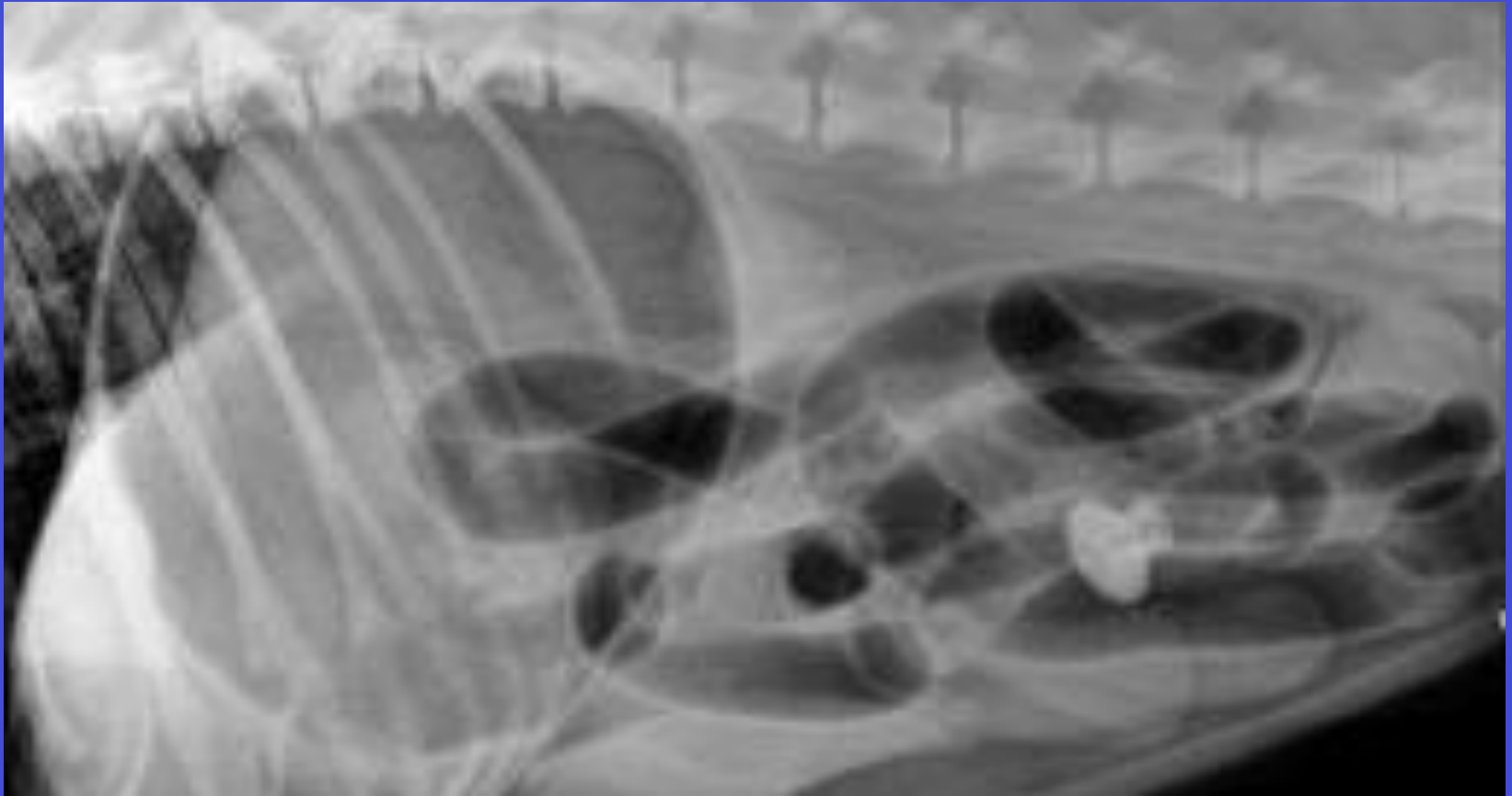

Figure 5. Lateral abdominal radiograph of a cat with intestinal plication and tapered gas

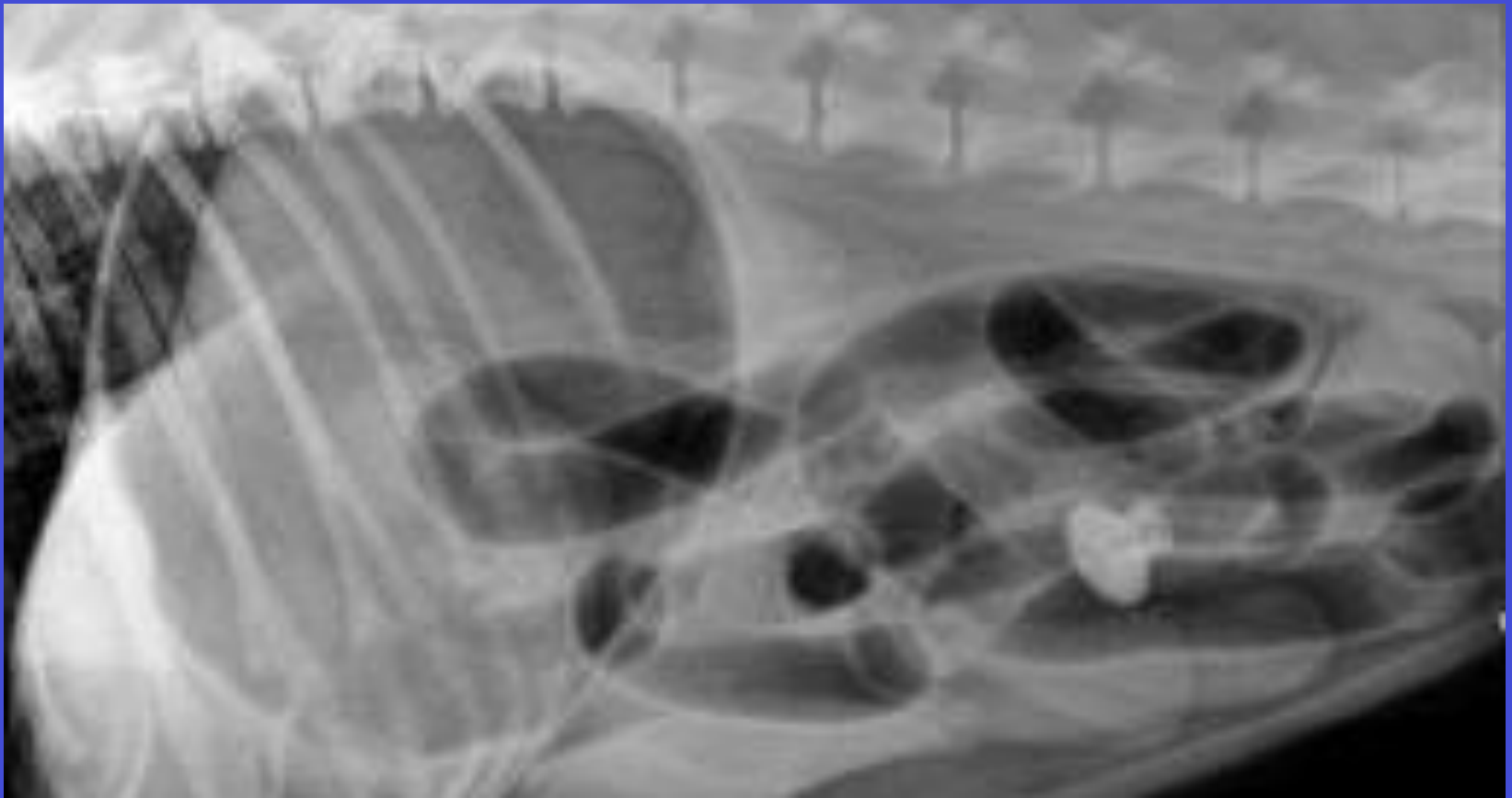Case # 6

- Rafter is a 5 year old male Border Terrier who vomited 5 times this morning and is completely anorexic.
- You decide to do an abdominal x-ray.

Abdominal x-ray Left Lateral



Small Intestinal Foreign body

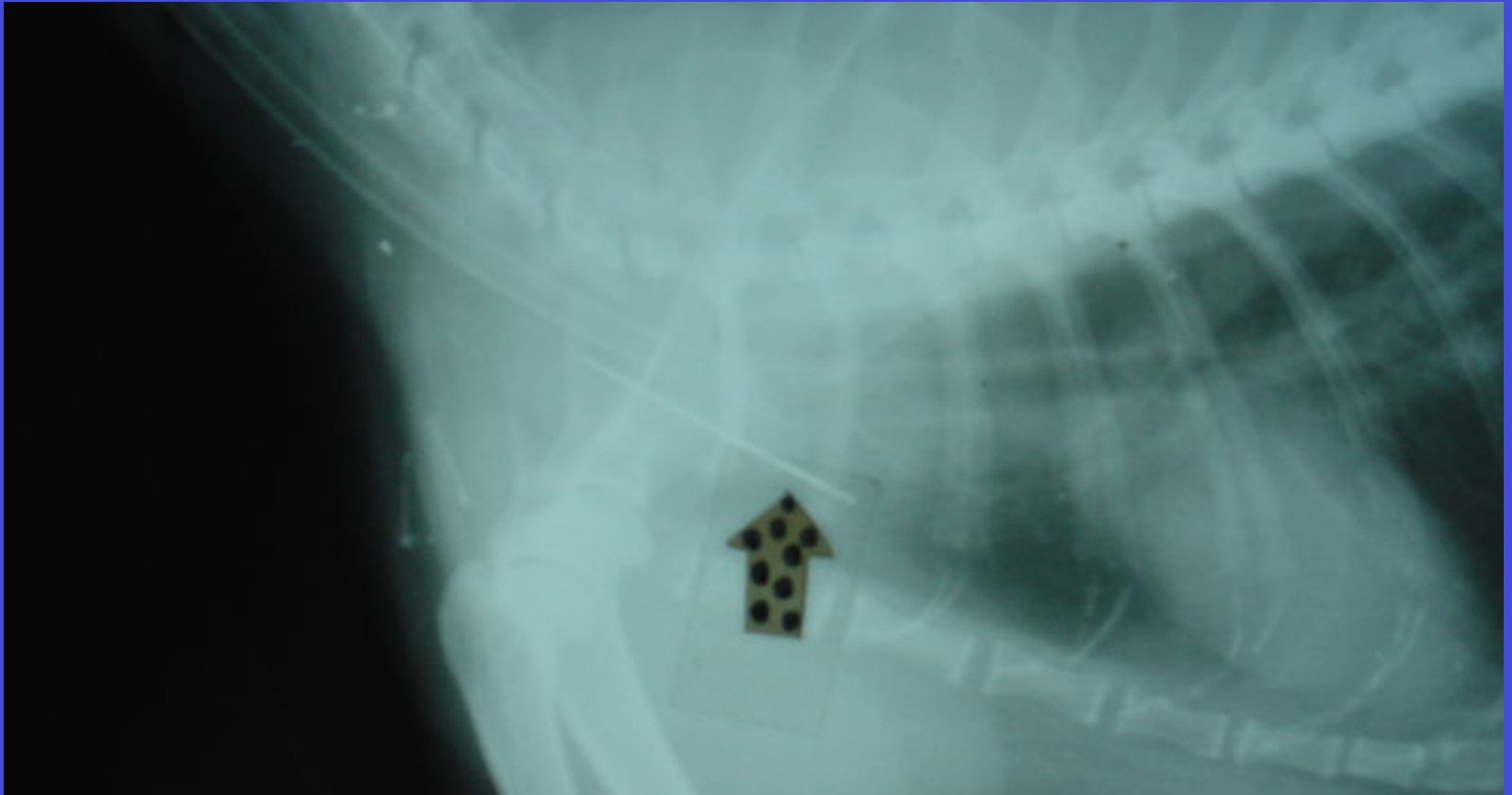


Case # 7

- Felix is a 4 year old DSH cat who started to salivate this morning. You look down her throat but can't see anything abnormal.
- You decide to do a radiograph of the larynx and trachea including the thorax.

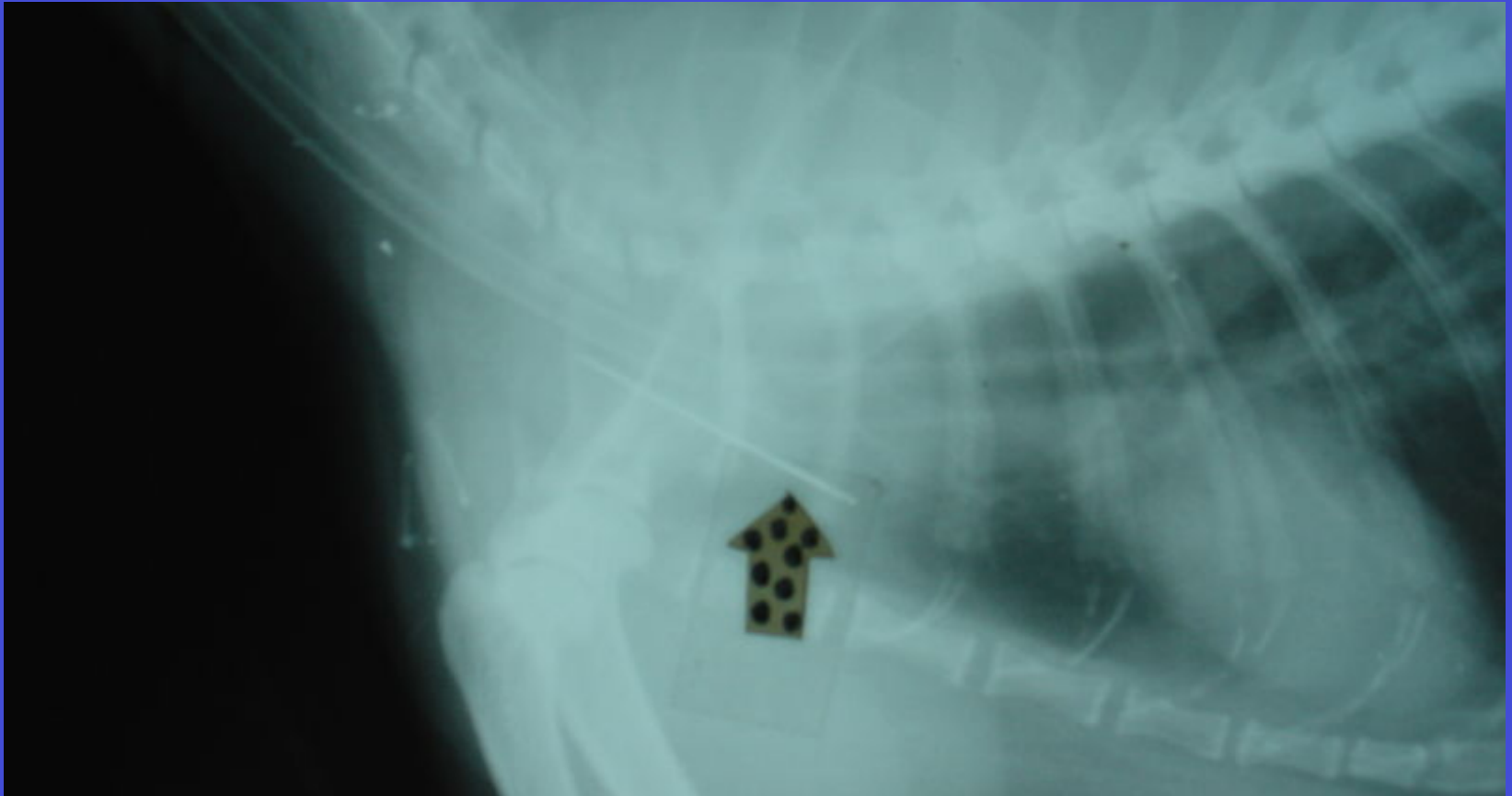
Thoracic Radiograph

including the larynx and trachea.



Thoracic Radiograph

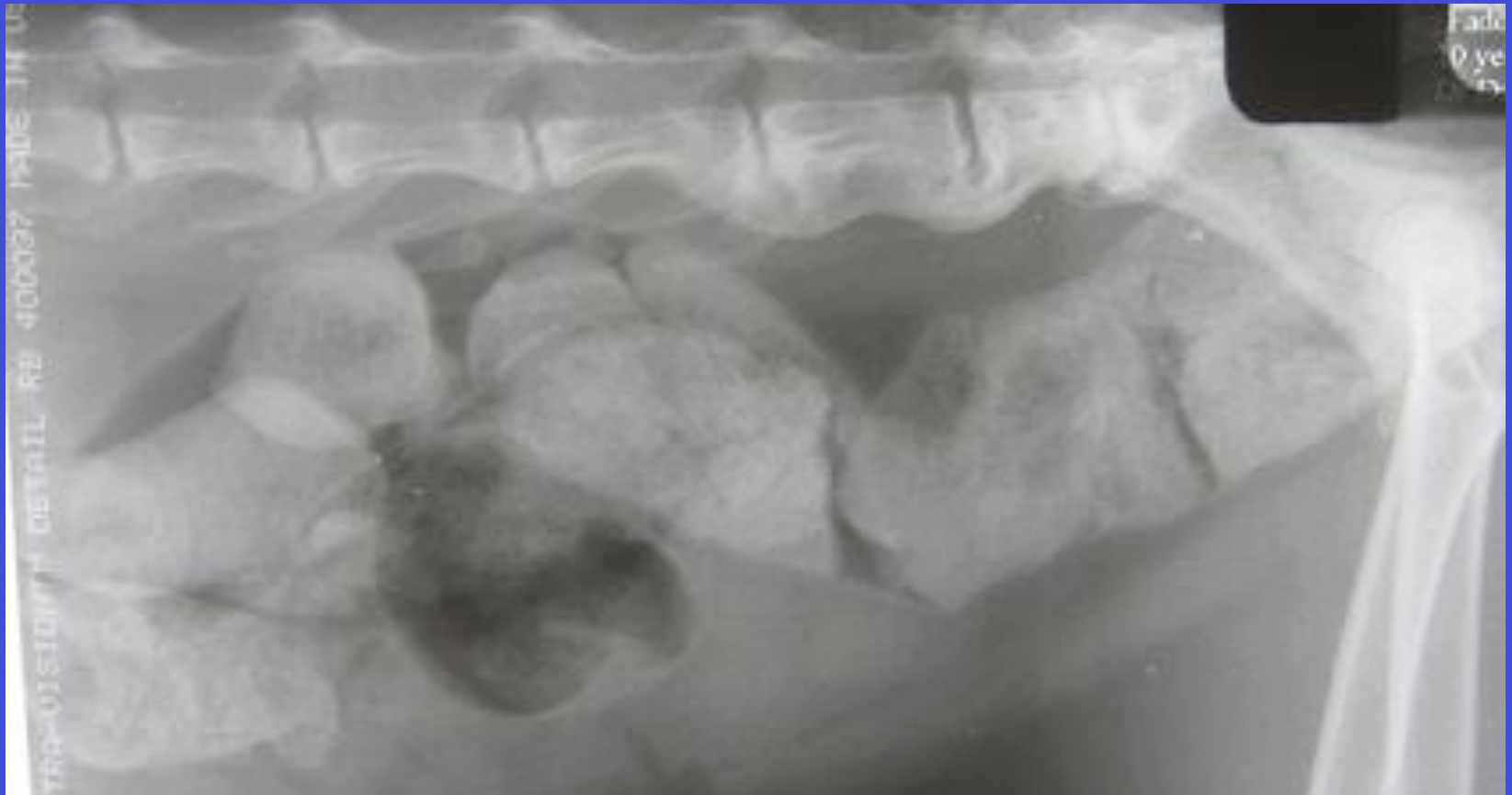
Needle lodged in the esophagus.



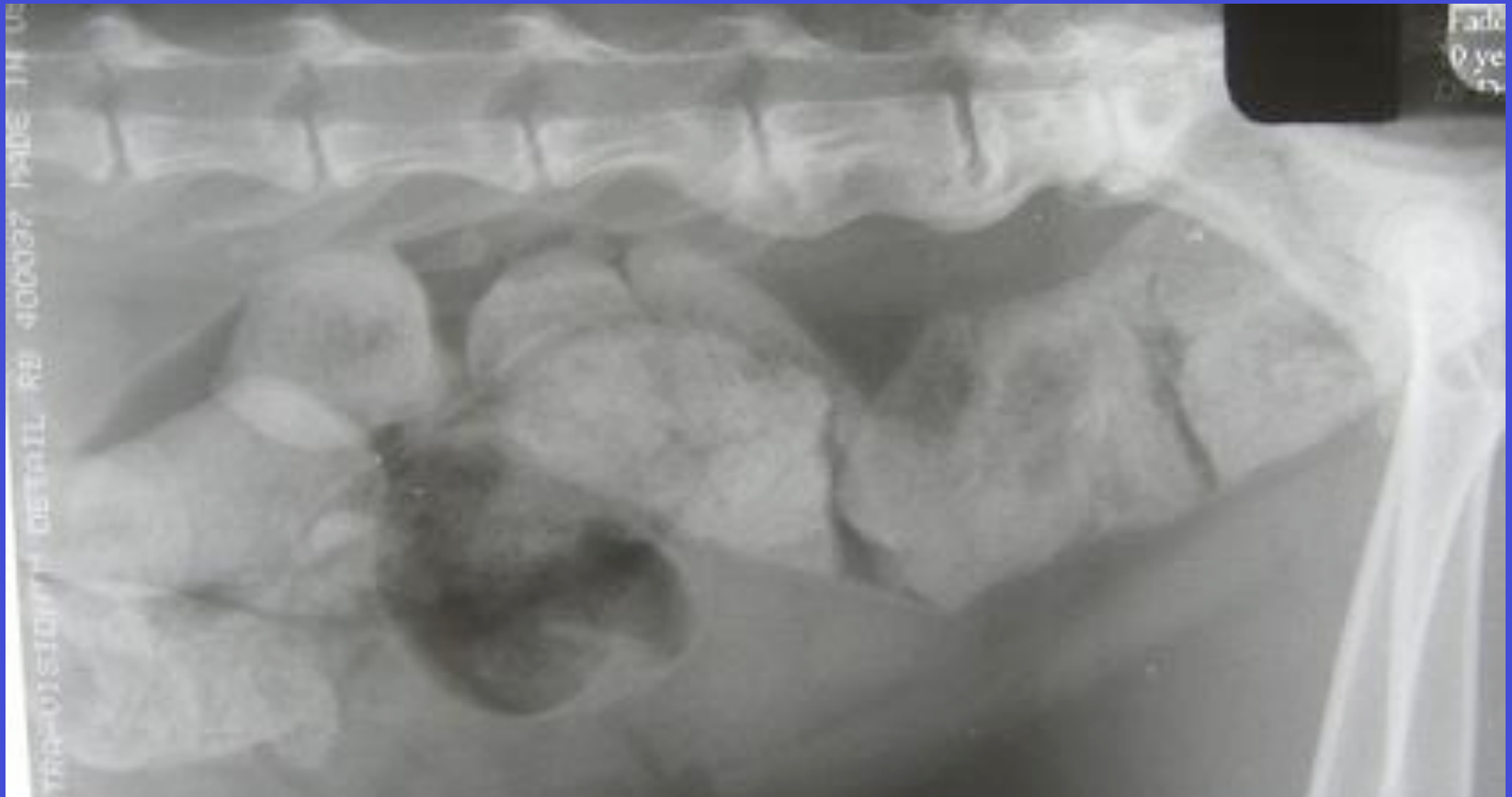
Case # 8

- Spike is a 7 year old DSH cat that has become completely anorexic for the last 3 days. The abdomen seems to be slightly enlarged.
- You decide to do an abdominal radiograph

Abdominal radiograph Left Lateral



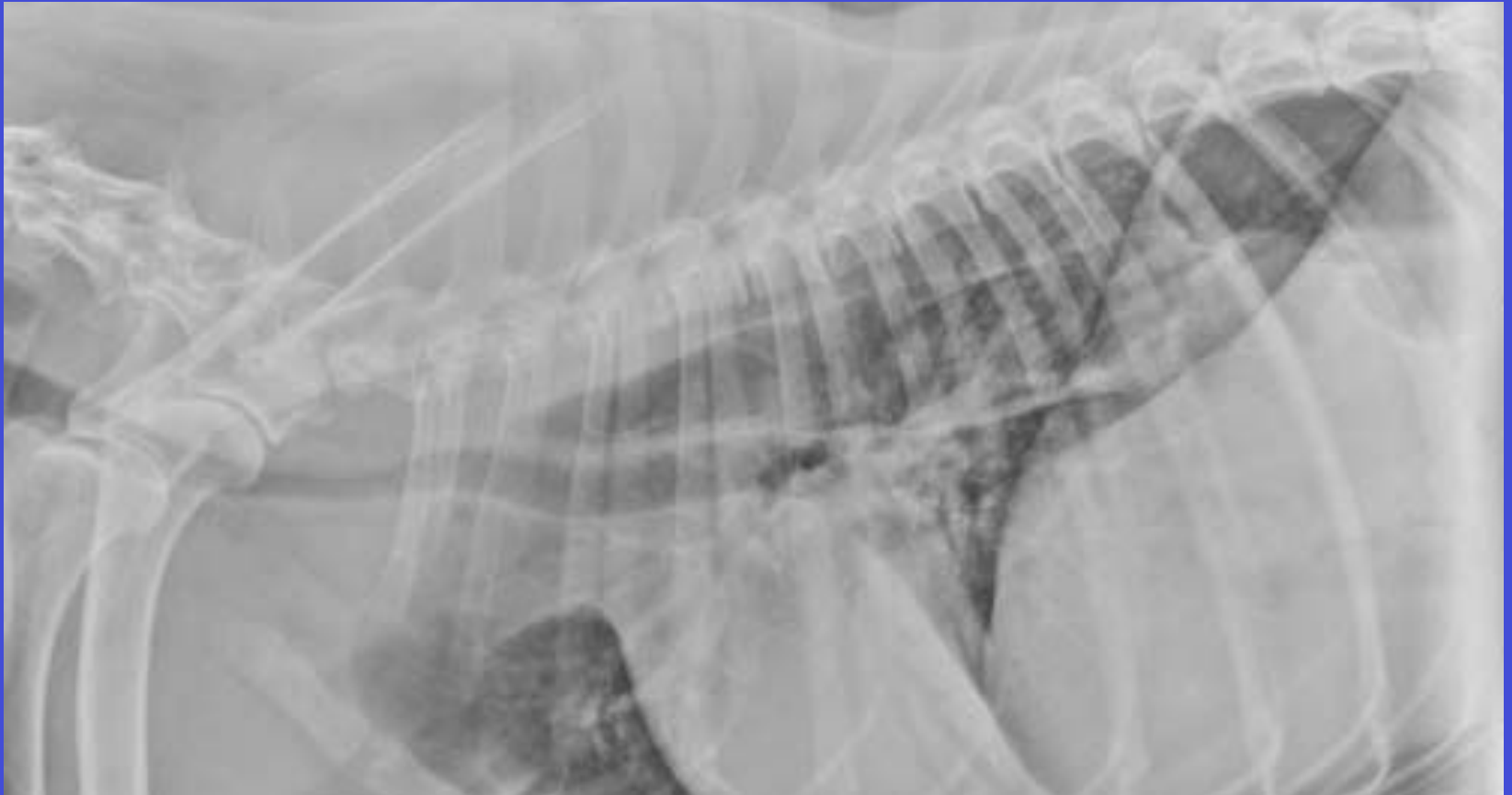
Colon Fecal Impaction



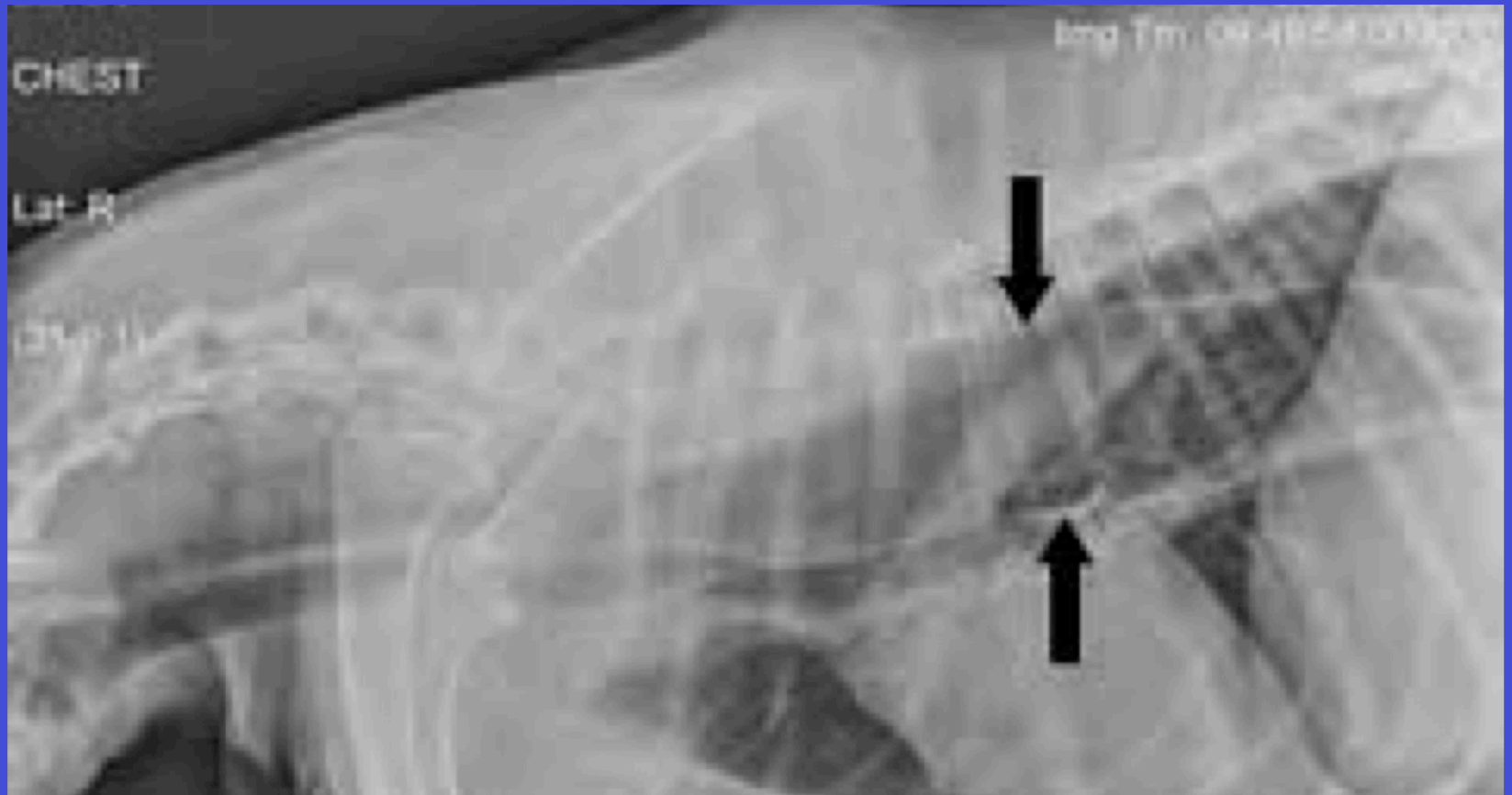Case # 9

- Champ is a 1 year old German Shepard who started regurgitating his food over the last few days. He drinks water normally but regurgitates his solid food.
- You decide to do a Thoracic radiograph

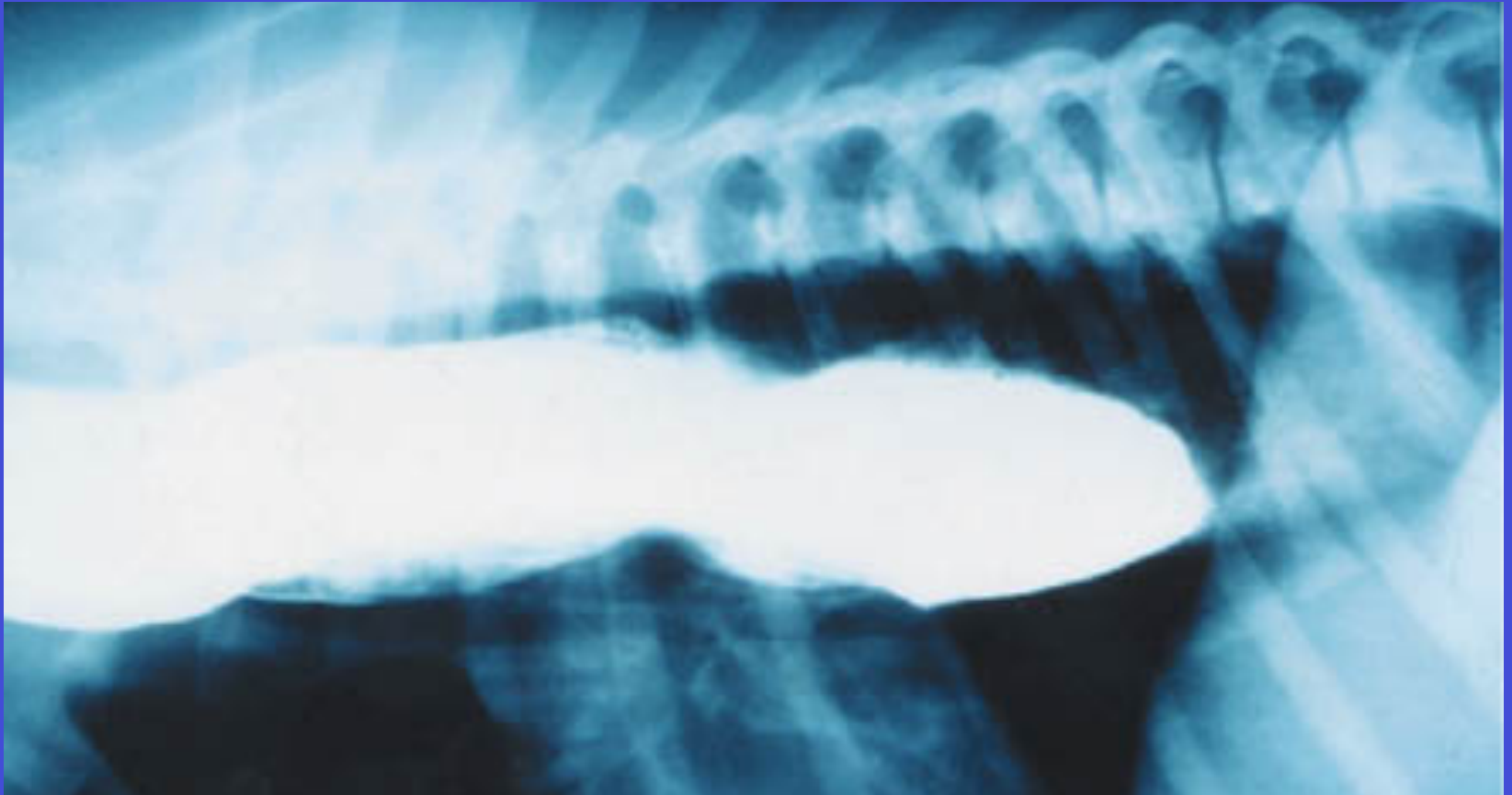
Thoracic left lateral view



Megaesophagus



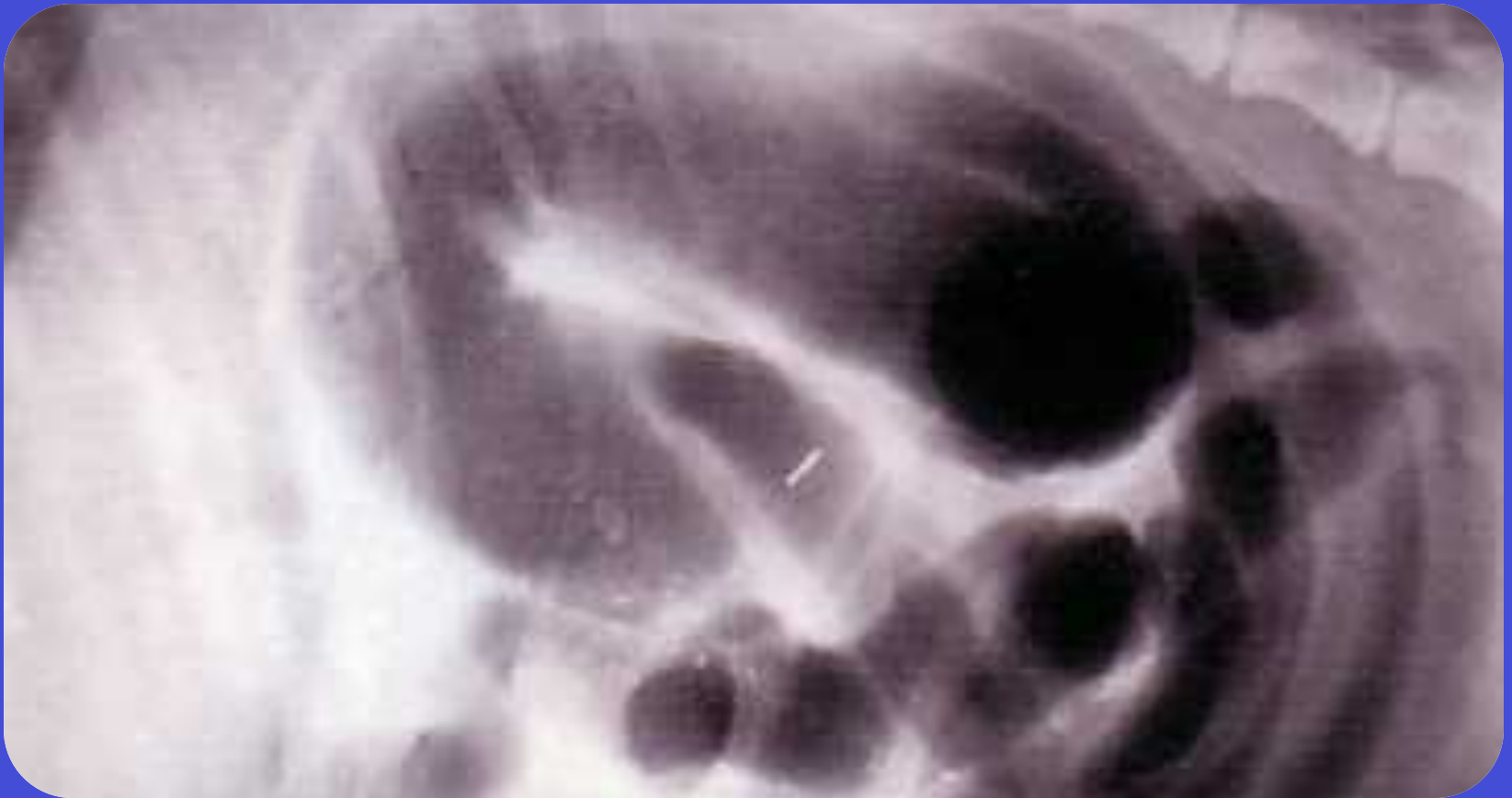Barium per os



Case # 10

- Brutus is a 8 year old Great Dane who became acutely lethargic this morning. He is completely anorexic. The owner also said he vomited 4 times this morning.
- He shows pain when his abdomen is palpated.
- You decide to do an abdominal radiograph.

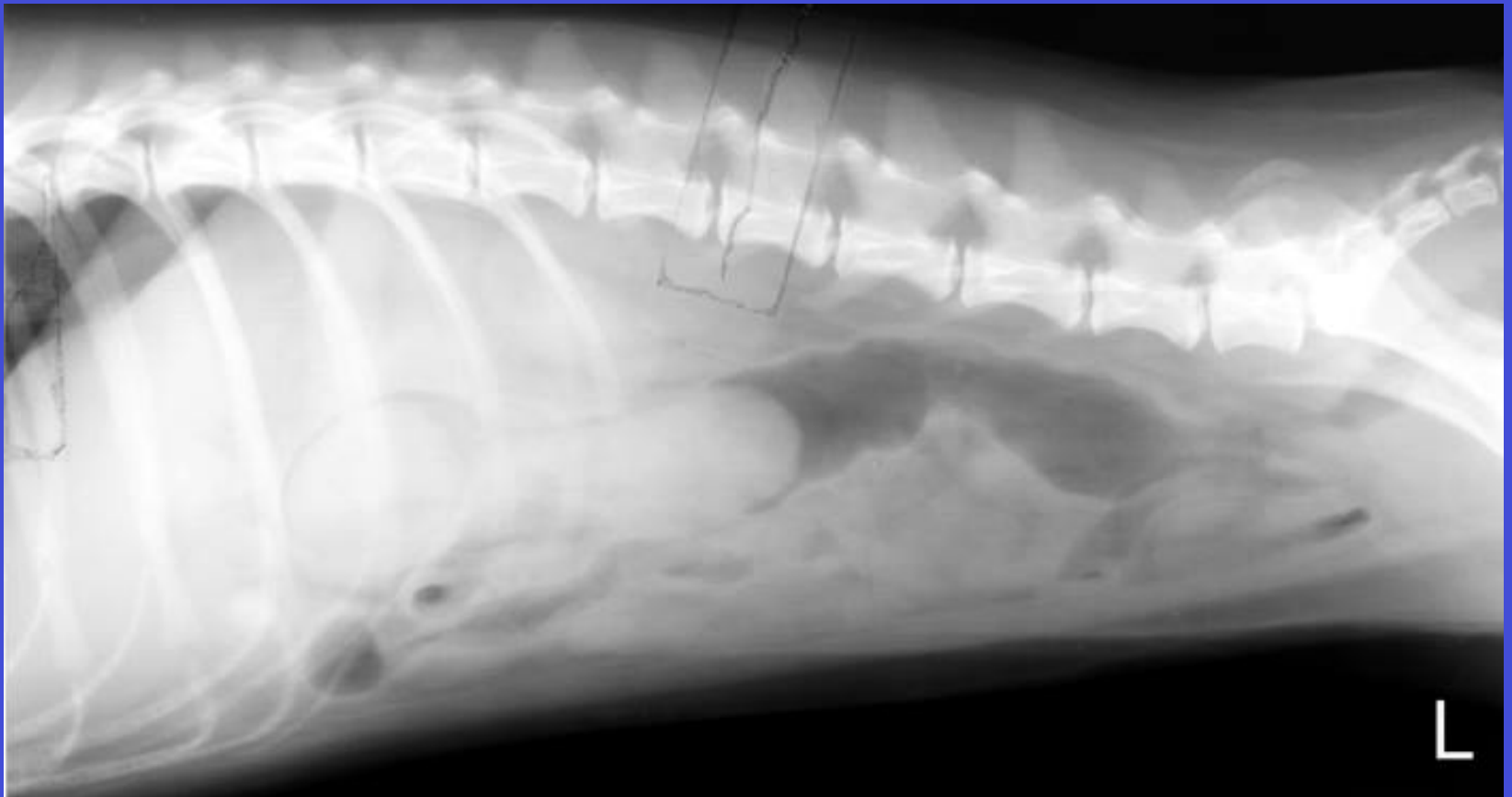Mesenteric Torsion



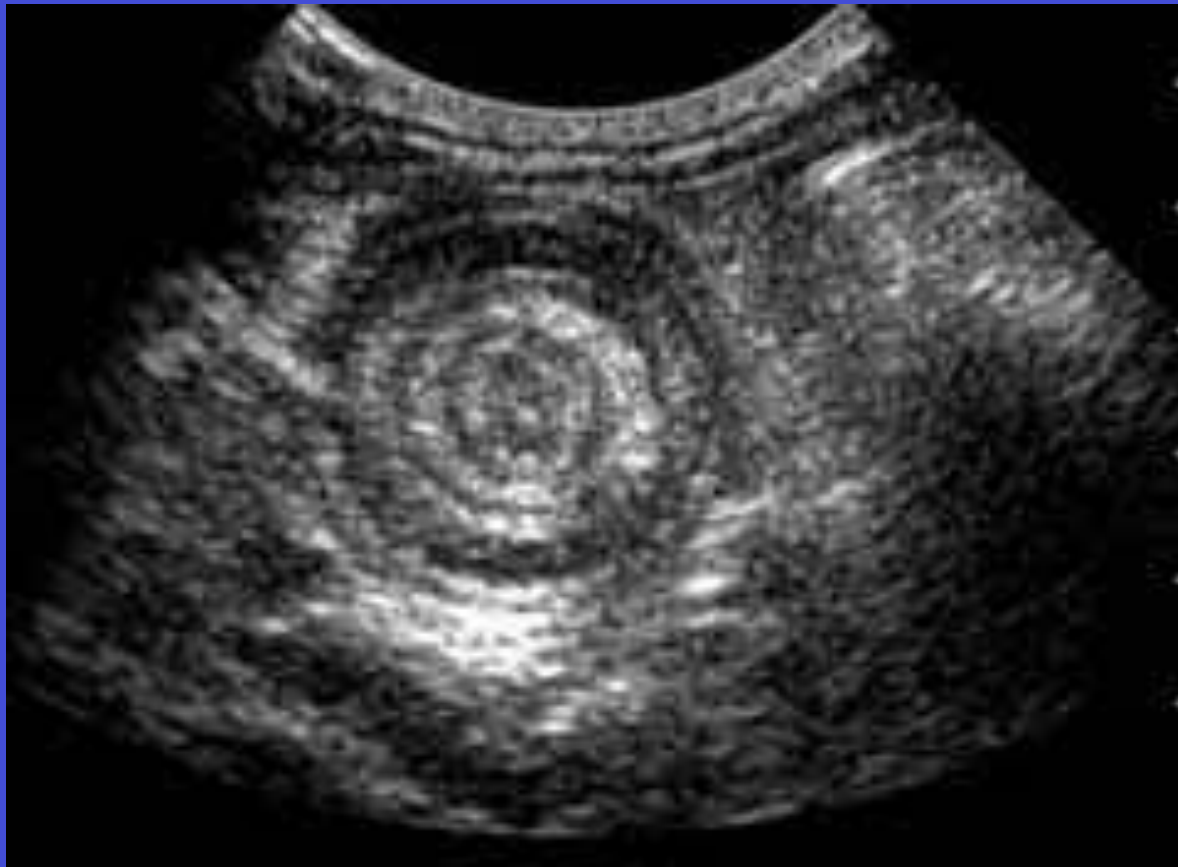Case # 11

- Ruby is a 4 month old black labrador who didn't eat this morning, had bloody diarrhea and was quite lethargic.
- You palpate a mass in the posterior abdomen
- You decide to do an abdominal radiograph.

Abdominal x-ray



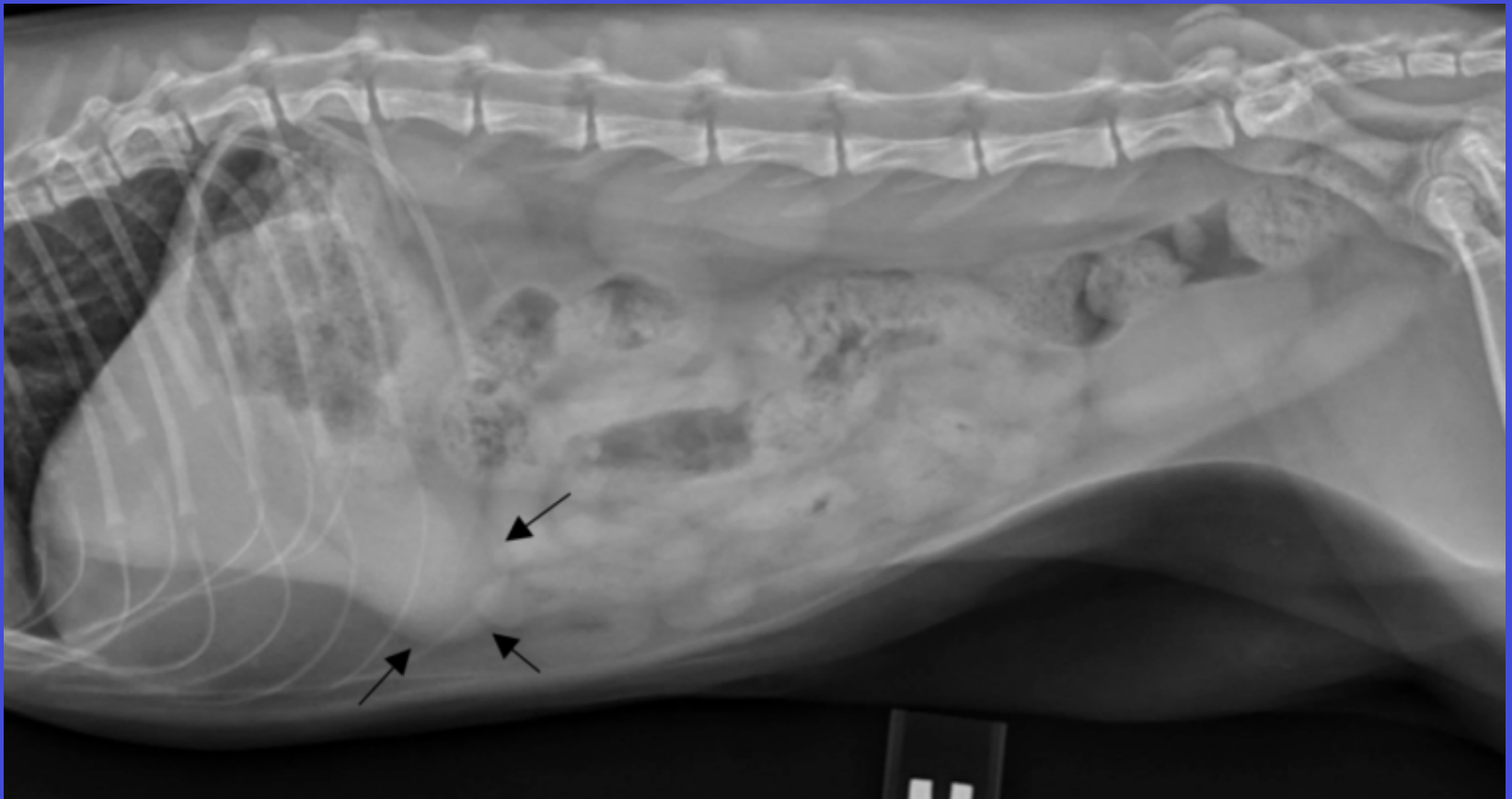
U/S of the posterior abdomen



Case # 12

- Flicka is a 5 year old Pekinese that vomited 2 times this morning. The owner thought she ate something in the backyard.
- You decide to do an abdominal x-ray.

Abdominal x-ray right lateral



Abdominal radiograph left lateral

normal gas filled pylorus

