

DERMATITIS IN DOGS

DR ANNIE VARGHESE, MVSc (Sur), PhD

COMPANION ANIMAL PRACTITIONER

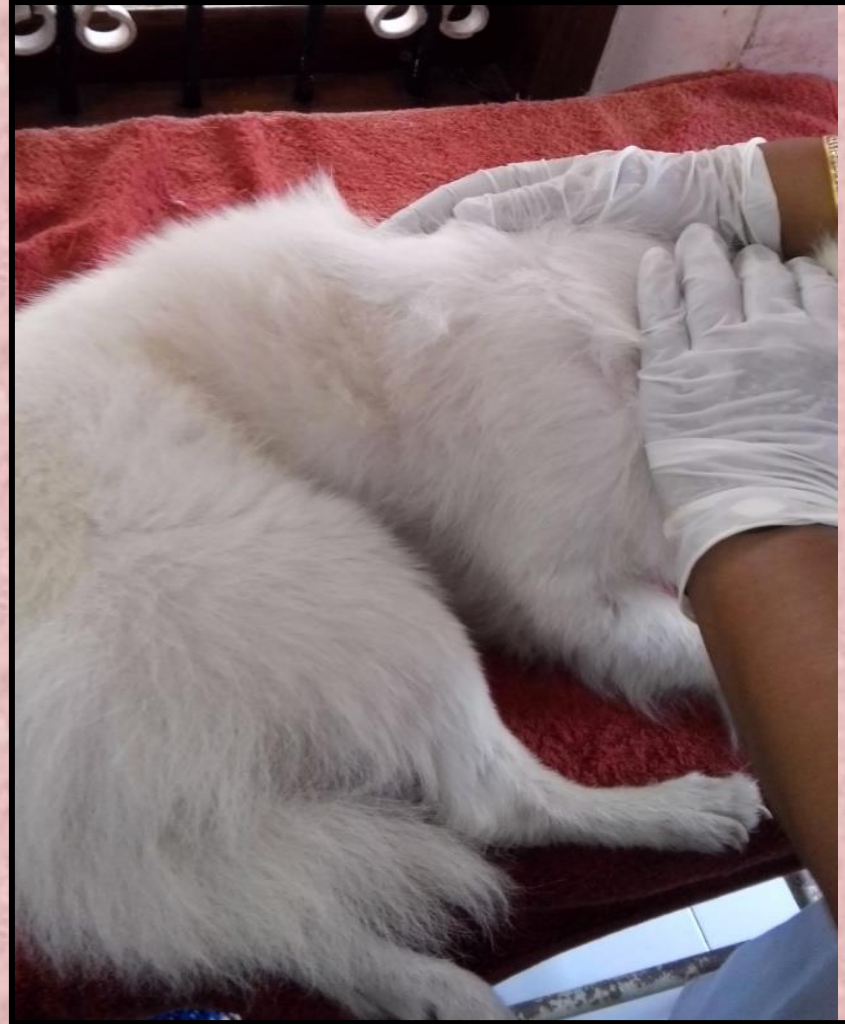THIRUVANATHAPURAM

A HEALTHY DOG

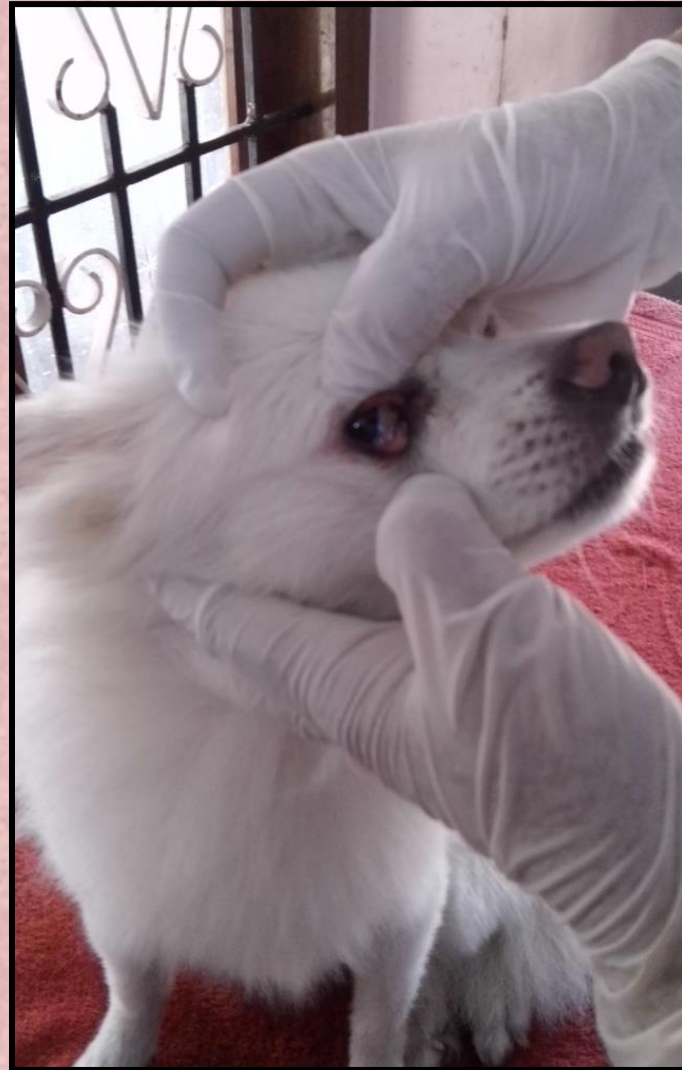
- ◉ Moist & bright eyes
- ◉ Clean ears
- ◉ Soft skin
- ◉ Smooth & shiny hair coat
- ◉ Clean teeth
- ◉ Pink gums
- ◉ Alert and active



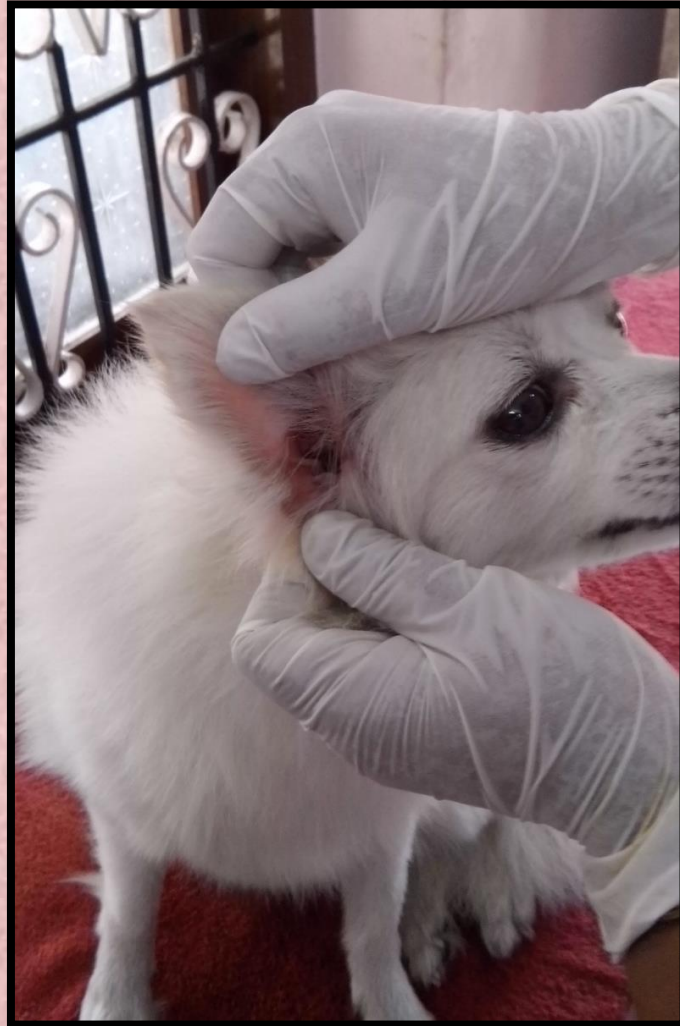SKIN AND HAIR COAT – soft, combed




HEALTHY DOG – eyes, moist, bright



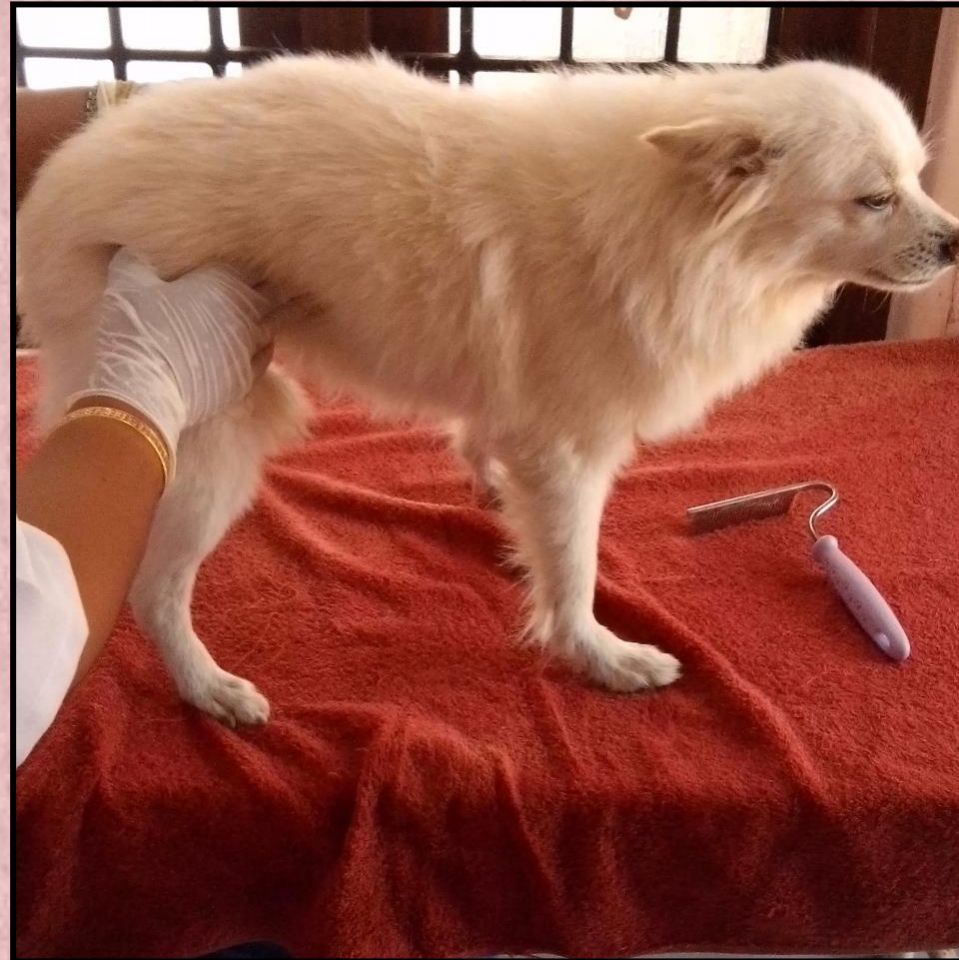EARS – clean, without debris



GUMS – pale rosette



ABDOMEN – not bloated, tucked in



HEALTHY BODY SCORE

A UNDERFED



B IDEAL BODY CONDITION








C OVERFED



BODY CONDITION SCORE

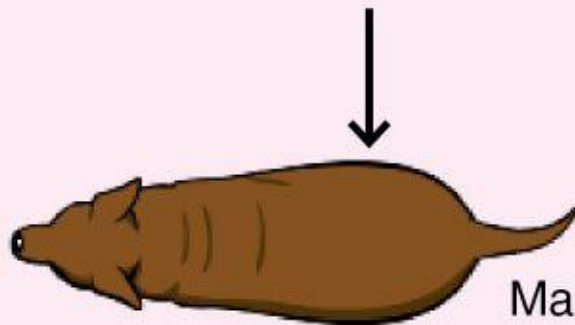
— SELECT A BODY CONDITION SCORE FOR YOUR PET —

| 1 | 2 | 3 | 4 | 5 |
|---|---|--|--|---|
|  |  |  |  |  |
| VERY THIN | UNDERWEIGHT | IDEAL | OVERWEIGHT | OBESE |
| <p>RIBS – Easily felt with no fat cover</p> <p>TAIL BASE – Bones are raised, no fat cover</p> <p>SIDE VIEW – Severe abdominal tuck</p> <p>OVERHEAD VIEW – Accentuated hourglass shape</p> | <p>RIBS – Easily felt with little fat cover</p> <p>TAIL BASE – Bones are raised with slight fat cover</p> <p>SIDE VIEW – Abdominal tuck</p> <p>OVERHEAD VIEW – Marked hourglass shape</p> | <p>RIBS – Easily felt with slight fat cover</p> <p>TAIL BASE – Smooth contour with slight fat cover</p> <p>SIDE VIEW – Abdominal tuck</p> <p>OVERHEAD VIEW – Well-proportioned waist</p> | <p>RIBS – Difficult to feel under moderate fat cover</p> <p>TAIL BASE – Some thickening, bones palpable under moderate fat cover</p> <p>SIDE VIEW – No abdominal tuck</p> <p>OVERHEAD VIEW – Back is slightly broadened at waist</p> | <p>RIBS – Difficult to feel under thick fat cover</p> <p>TAIL BASE – Thickened and difficult to feel under thick fat cover</p> <p>SIDE VIEW – No waist, fat hangs from abdomen</p> <p>OVERHEAD VIEW – Back is markedly broadened at waist</p> |

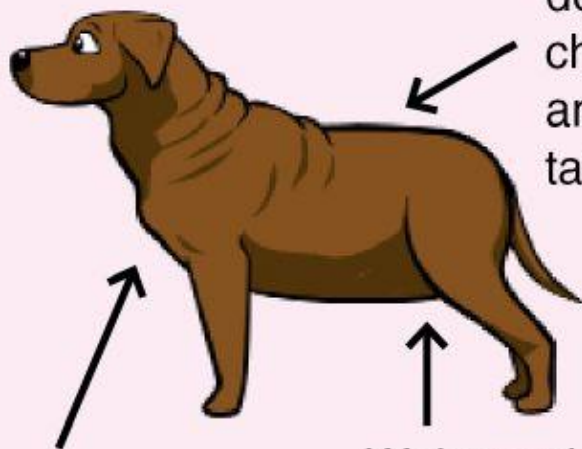
OBESE DOGS

9

Obvious abdominal distension



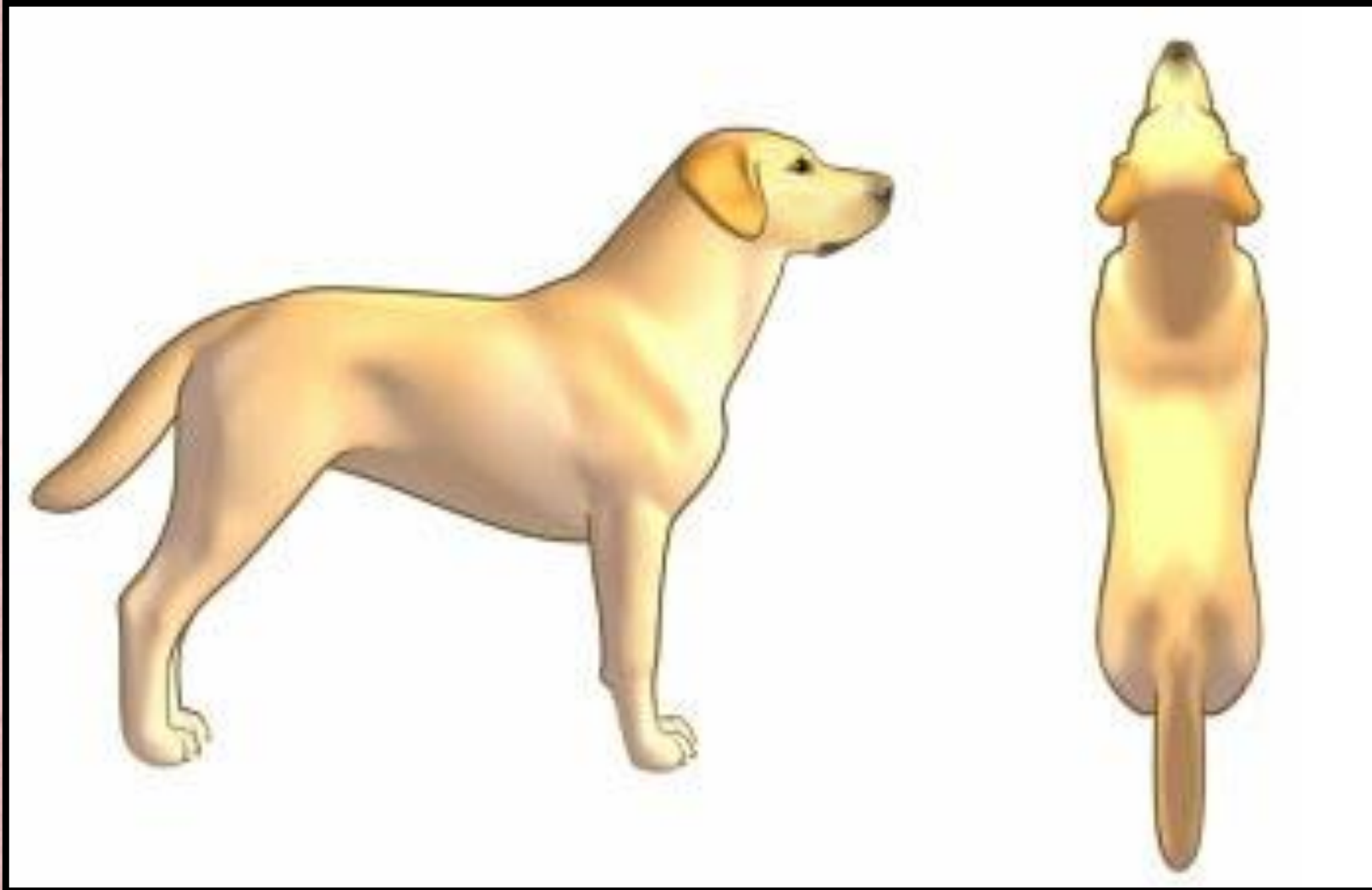
Massive fat deposits over chest, spine, and base of tail



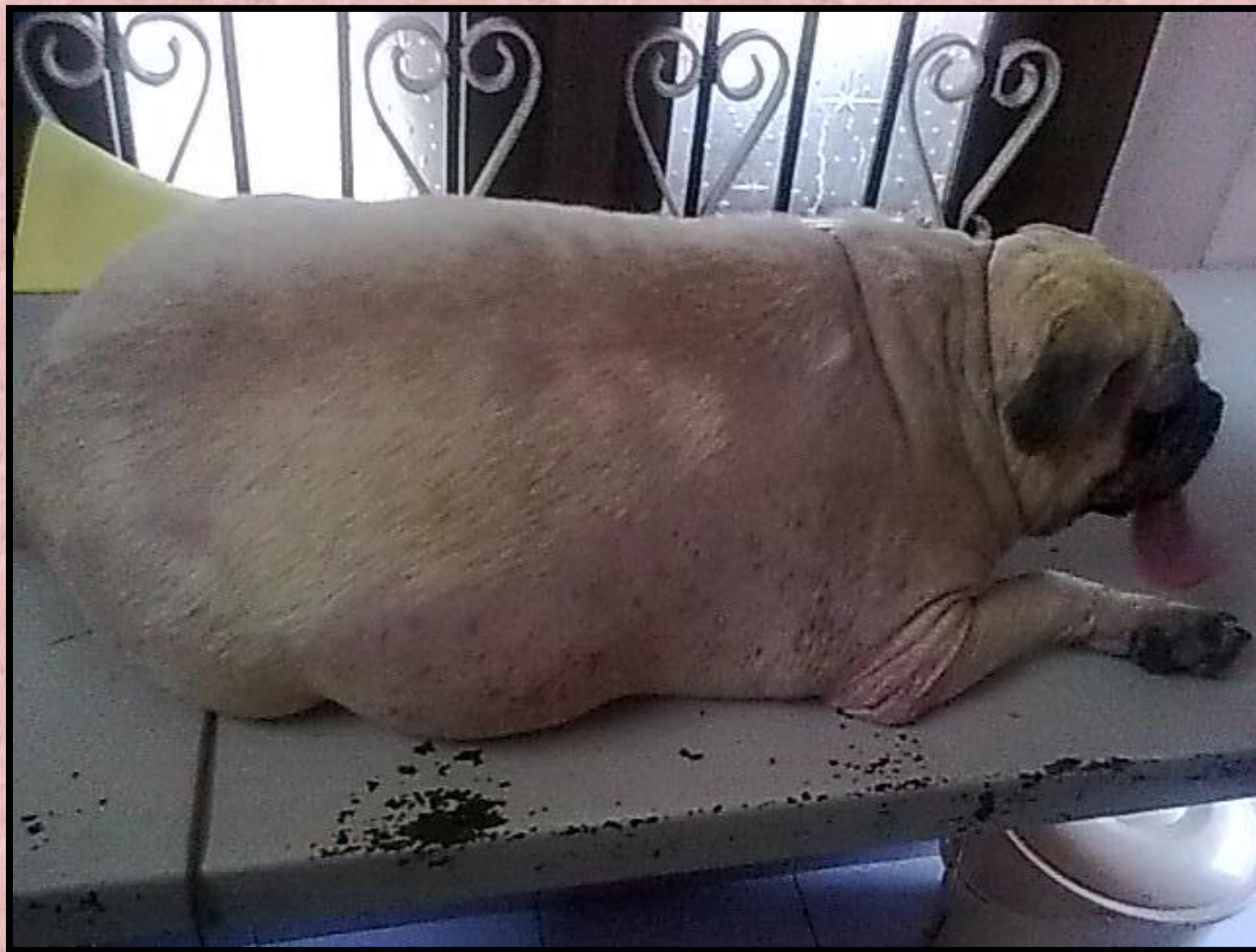Fat deposits on neck and limbs

Waist and abdominal tuck absent

HEALTHY BODY SCORE



Obesity



REQUIREMENTS FOR A HEALTHY SKIN

- **DIETARY REQUIREMENTS**
- **BODY HYGIENE**
- **ENVIRONMENT**
- **EXERCISE**

DIETARY REQUIREMENTS

- ◉ **Water**
- ◉ **Energy**
- ◉ **Carbohydrates**
- ◉ **Fat**
- ◉ **Protein**
- ◉ **Vitamins**
- ◉ **Minerals**
- ◉ **Fiber**

A HEALTHY DIET

- ◉ **Water** 60ml/kg/day; vegetables, milk
- ◉ **Energy** } **Rice, wheat,**
- ◉ **Carbohydrates** } **fried food**
- ◉ **Fat** } **Beef, egg,**
- ◉ **Protein** } **Fish, chicken, meat, pulses,**
egg white
- ◉ **Vitamins** } **Vegetables, fruits**
- ◉ **Minerals** } **Bones, salt, fish, vegetables,**
milk, fruits
- ◉ **Fibre** } **Vegetables, fruits**

BODY HYGIENE

- Daily brushing esp in hairy, furry dogs
- Bathing with dog shampoos (weekly, monthly, bi/triweekly)
- Anti tick / anti flea treatment (prior to monsoons)
- Grooming (eyes, ears, nails, fur)
- Diet
 - ✓ - Fibre
 - ✓ - Water
 - ✓ - Vitamins (A, D3, biotin, E etc)
 - ✓ - Minerals
- Exercise
- Proper resting area – good ventilation, cool

Different skin lesions - primary

Alopecia – loss of fur (generalized /local)

- ❑ Macules – non elevated areas of discoloration
- ❑ Papules – elevated areas of discoloration
- ❑ Vesicles – fluid filled lesions
- ❑ Wheals - elevations which are flat topped, erythematous
- ❑ Nodules – larger elevations
- ❑ Tumours

Different skin lesions - secondary

- ❑ Epidermal collarettes (later stages of pustules & vesicles)
- ❑ Scars
- ❑ Excoriation (self trauma)
- ❑ Erosions / Ulcers (loss of epidermis)
- ❑ Fissures (loss of dermis)
- ❑ Lichenification (thickening & dark pigmentation)
- ❑ Callus (esp at elbow & hock joint)

Different skin lesions - others

- Alopecia
- Scale and/or crusts
- Hot spots
- Follicular casts (plugging of hair follicles with visible keratin)
- Comedones (blackheads)
- Pigment changes
- Erythema

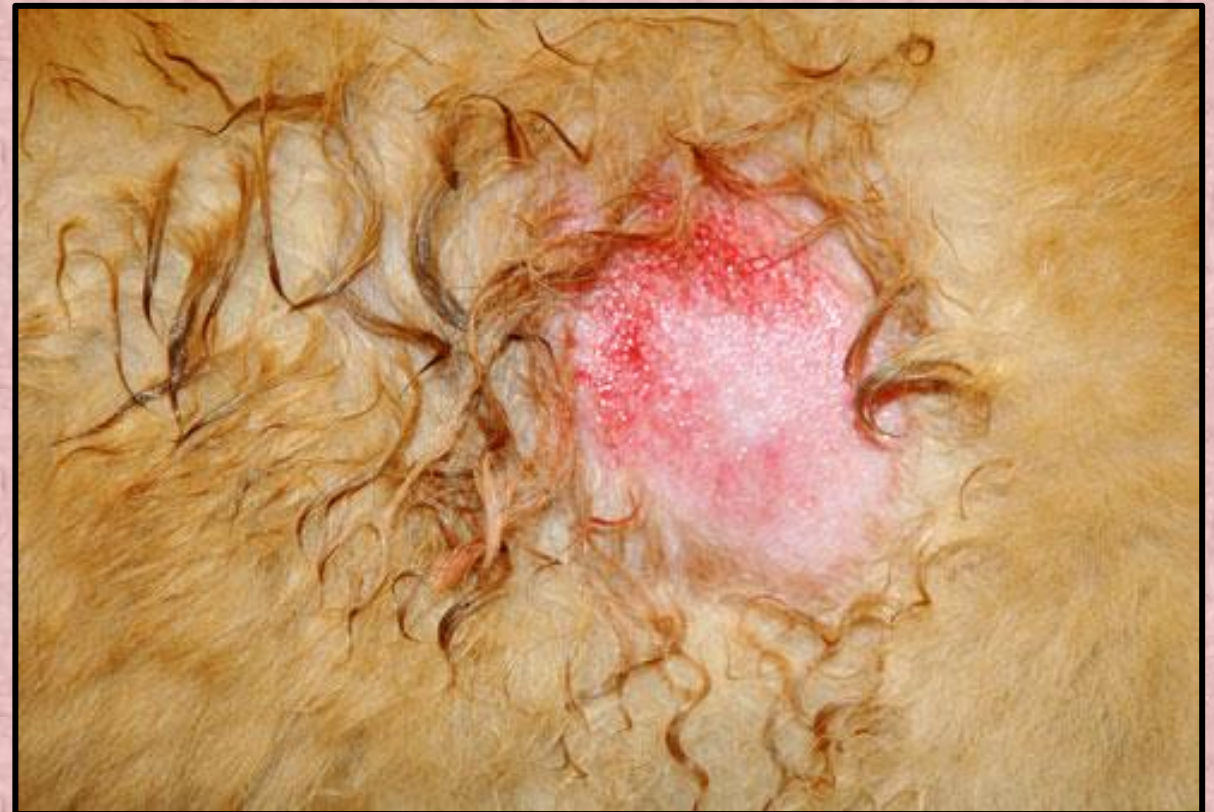Common causes for skin problems

- Bacteria
- Fungi, yeast
- External parasites
- Internal parasites
- Dry skin
- Dietary defects
- Lack of exercise
- Hormonal problems
- Allergy

Bacterial dermatitis

- ❖ Macules, papules
- ❖ Erythema
- ❖ Pustules
- ❖ Hot spots
- ❖ Oozing
- ❖ Itching
- ❖ Pain
- ❖ Inflammation

PYODERMA



Line of treatment – bacterial dermatitis

❑ Environment – hot , humid

❑ Floor cleaning – avoid Lysol etc.

- use cloth detergent, kennel hygiene

❑ Diet - fibre, water

❑ Soothing shampoo bath

– Episoothe, Allermyl, Oat shampoo, Zweena

- biweekly

❑ Local ointments

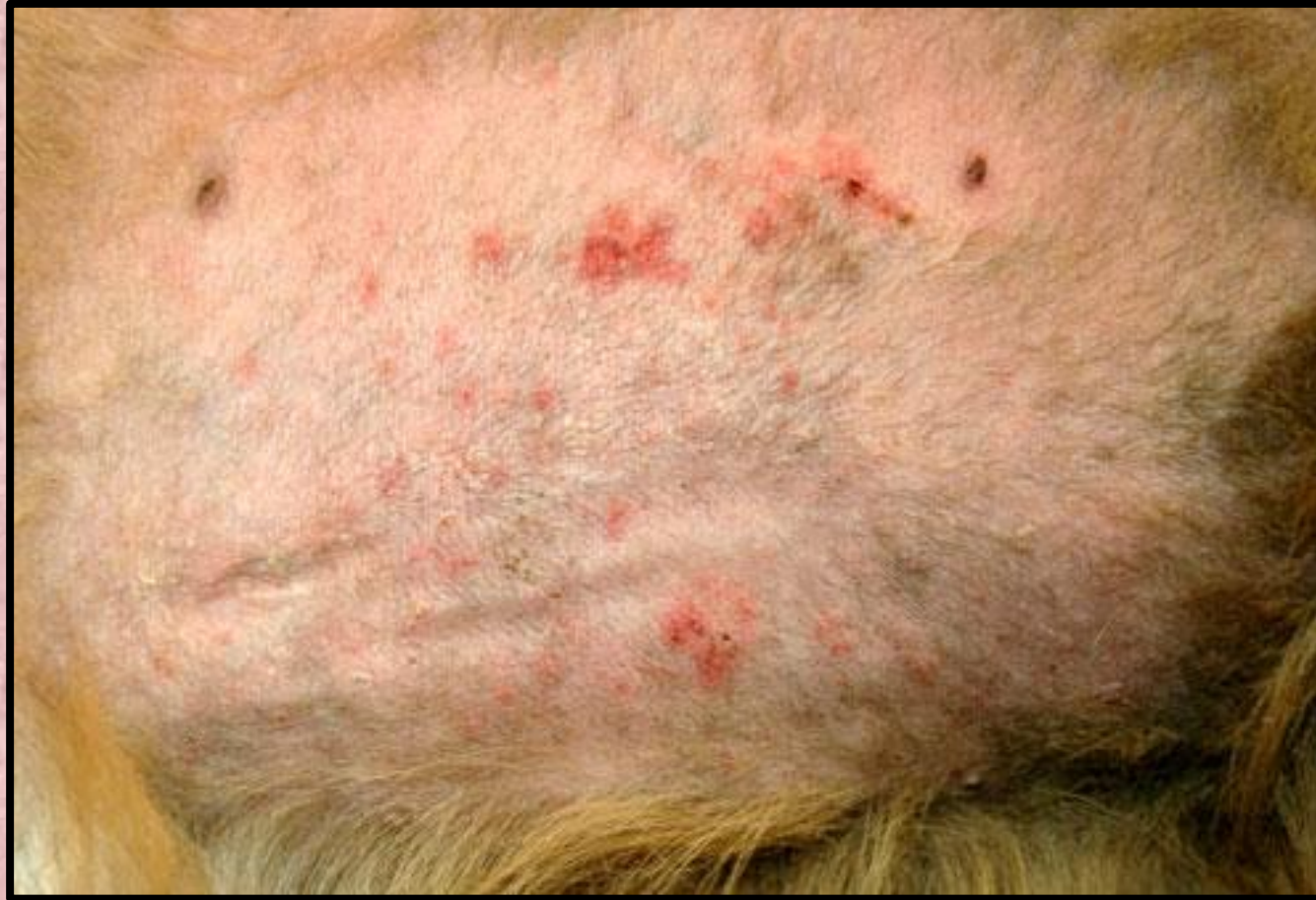– Vetbacin, Candiderma (after hypertonic saline wash)

Line of treatment – bacterial dermatitis

- ❑ Antibiotics – Cephalexin (10-30mg/kg b wt 12 hourly)
- ❑ - Enrofloxacin, Cefixime for 1 week
- ❑ – pulse therapy - gap for 1 week, repeat for 1 week
- ❑ Anti inflammatory
- ❑ – Meloxicam (0.2 mg/kg im), Serratiopeptidase tabs
- ❑ Anti histamines
- ❑ – Levucetrizine (1 or 1/2 Tab BD or OD as required)
- ❑ Correct deficiencies
- ❑ - Vit A, D3, E supplements (Nutriccoat Advance, Softcoat)

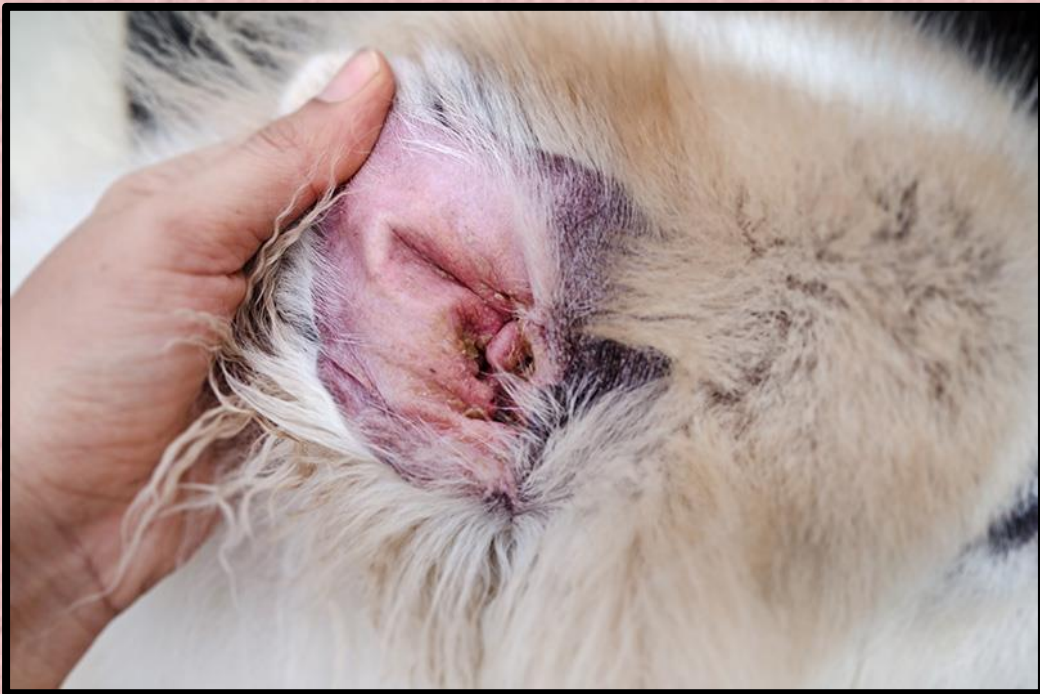Review – weekly at first, then biweekly till discharge

Folliculitis – inflammation of hair follicles

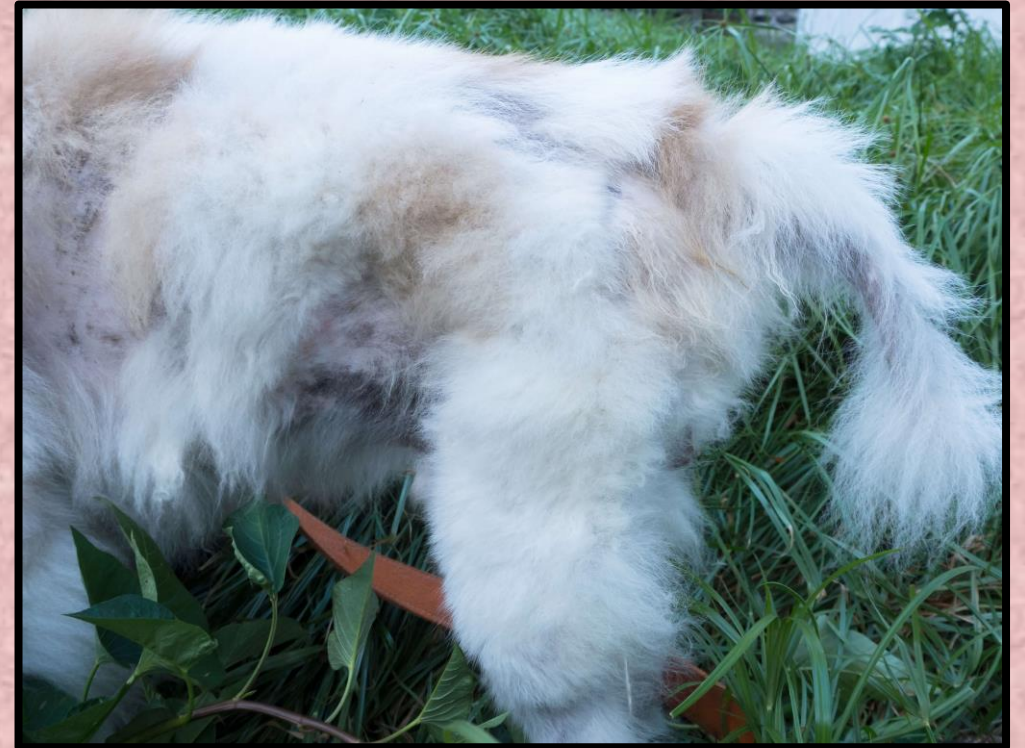

Fungal dermatitis

**DANDRUFF LIKE DUST,
ERYTHEMA, MILD FISSURES**



**ALOPECIA, ITCHING, BARE SKIN
PATCHES**



Fungal dermatitis

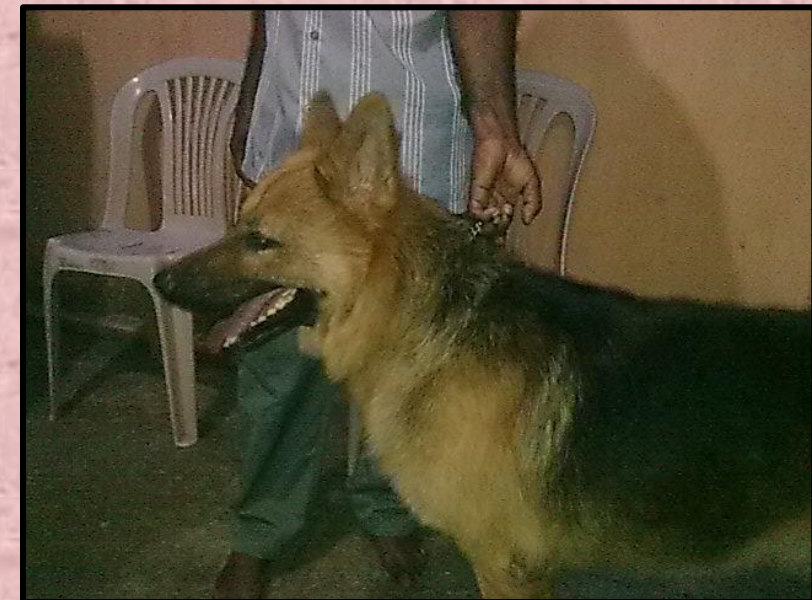CHRONIC FUNGAL DERMATITIS

- Alopecia
- Dandruff like whitish dust
- Itching esp at night
- Erythema initially
- Scales
- Crusts
- Follicular casts
- Hyper pigmentation
- Acanthosis later
- Lichenification



Fungal dermatitis – line of treatment

- ❑ Diet correction
- ❑ Environment correction – cool but dry
- ❑ Medication:
 - ◀ Shampoo – ketoconazole, miconazole
 - ◀ - once in 3 -4 days
 - ◀ Daily ointments – combination of antibacterial, antifungal, steroid
 - ◀ Antifungals – griseofulvin, ketoconazole, Itraconazole, Terbinafine
 - ◀ Liver protectants – Liv 52pet, Diarest Liv...
 - ◀ Antihistamines – levucetizine, cetizine
 - ◀ Vit A, D3 supplementation
 - ◀ Amino Acid supplementation

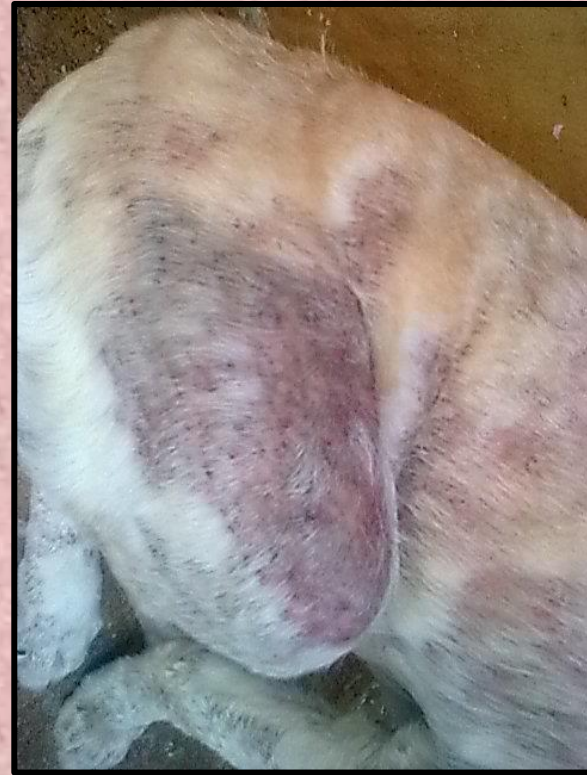
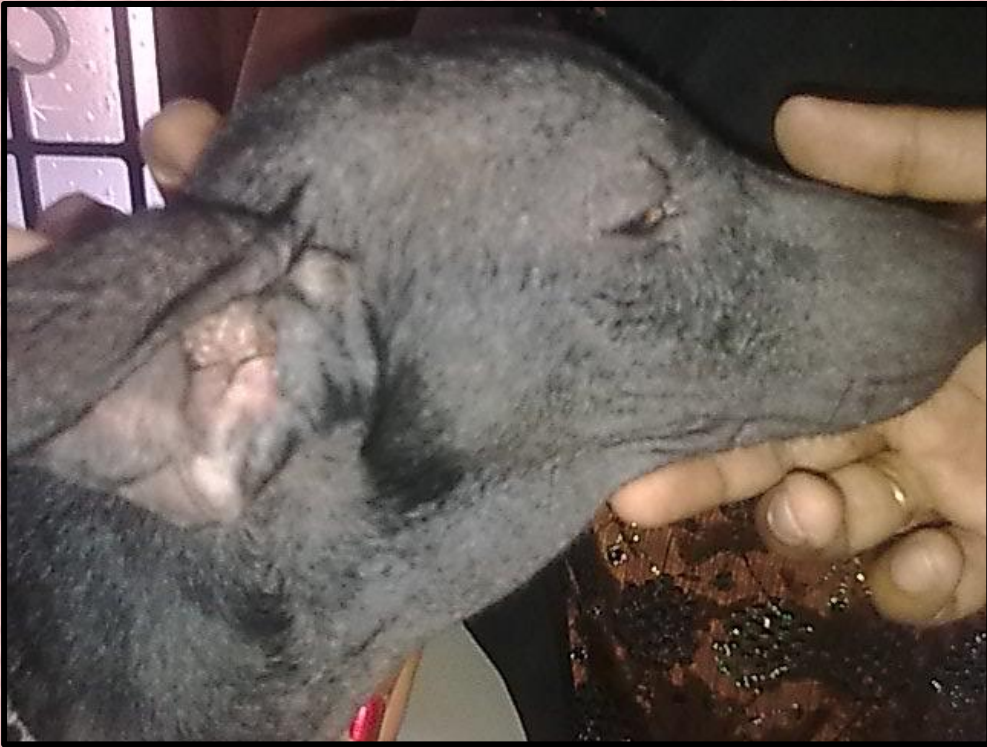
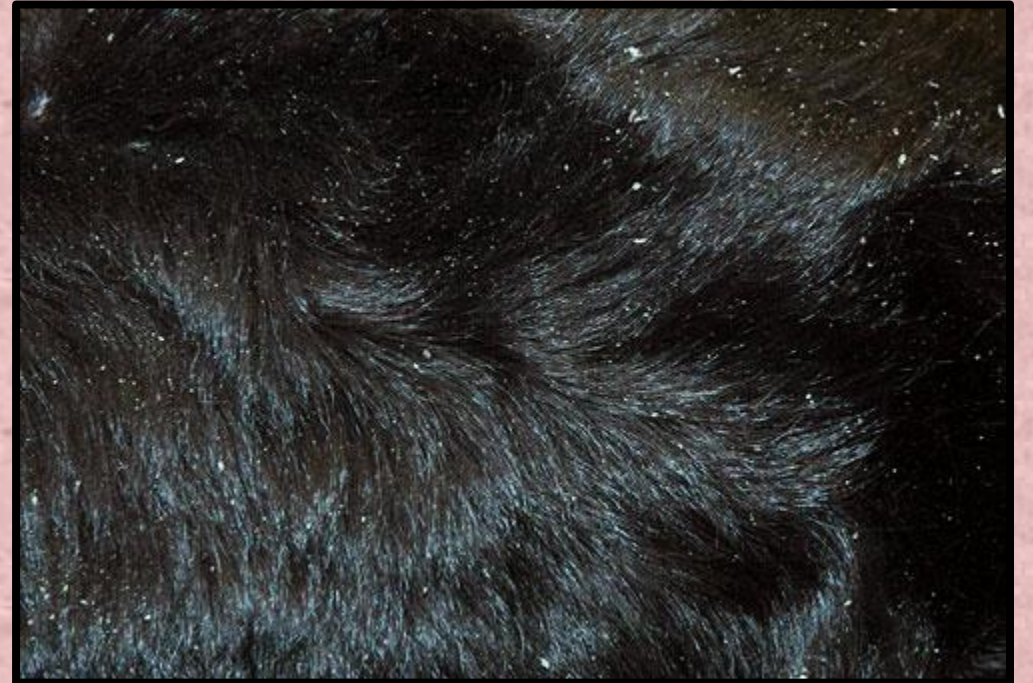
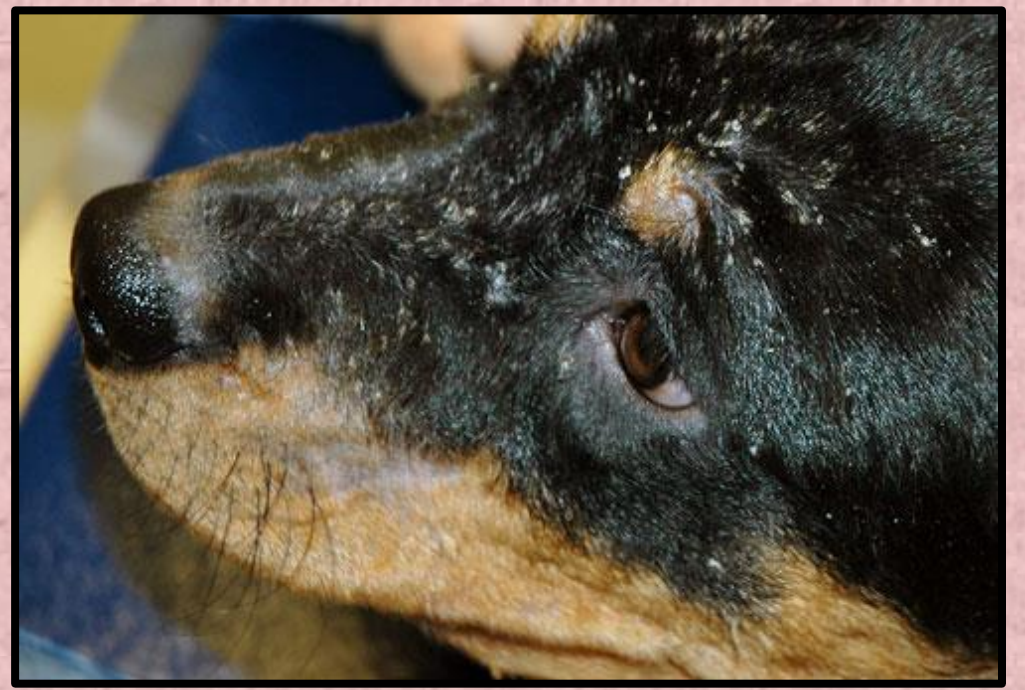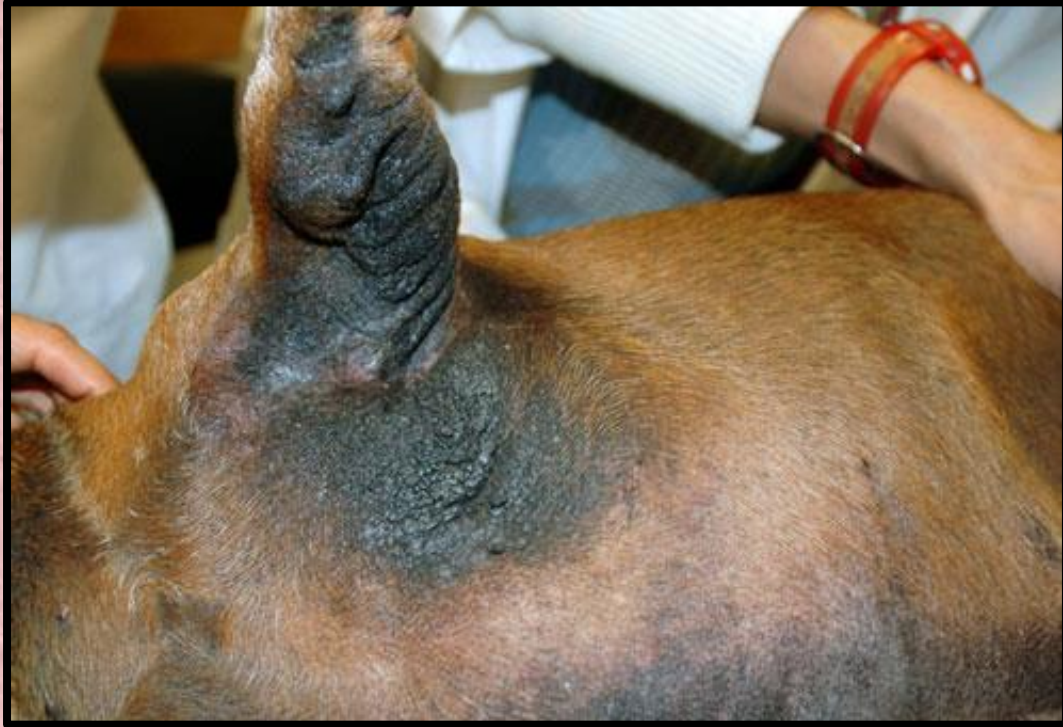Treatment continues - biweekly/monthly review

Fungal Dermatitis – Symptoms early



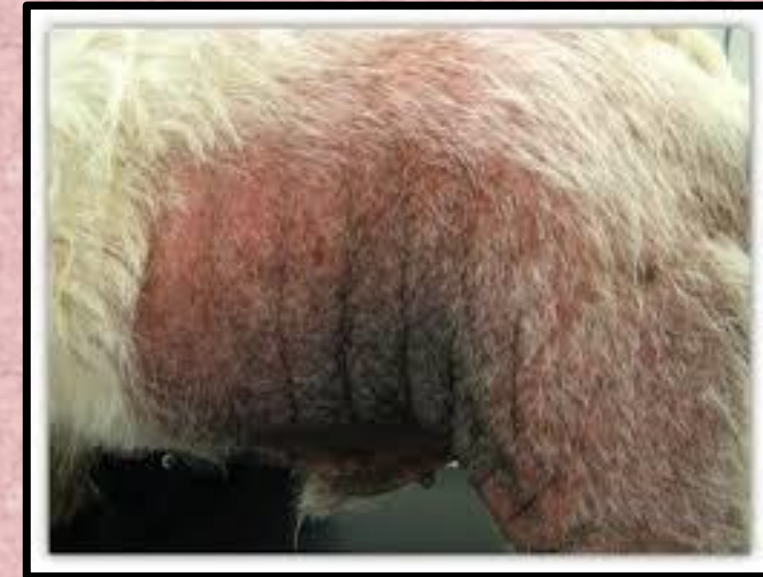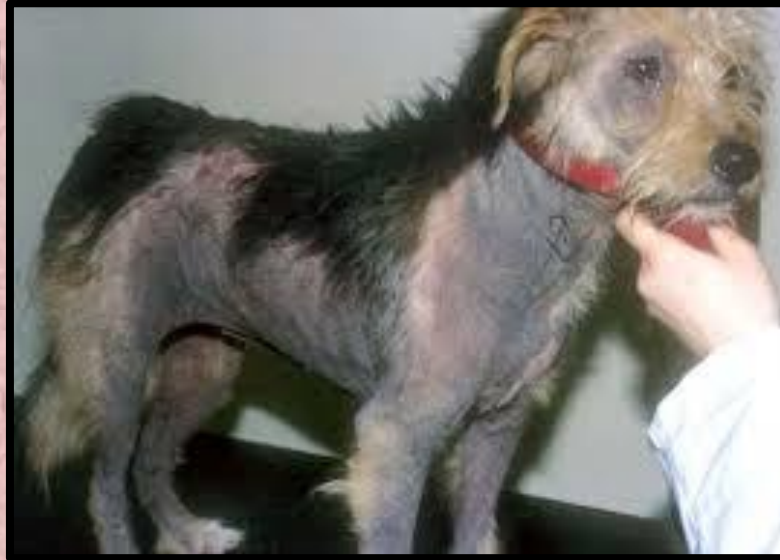Fungal Dermatitis – Symptoms chronic





Malassezia dermatitis - yeast

- ❖ Hyper pigmentation – blackish
- ❖ Sour bad smell – typical
- ❖ Severe itching
- ❖ Alopecia
- ❖ Crusts , scales
- ❖ Excoriations
- ❖ Fissures
- ❖ Lichenification



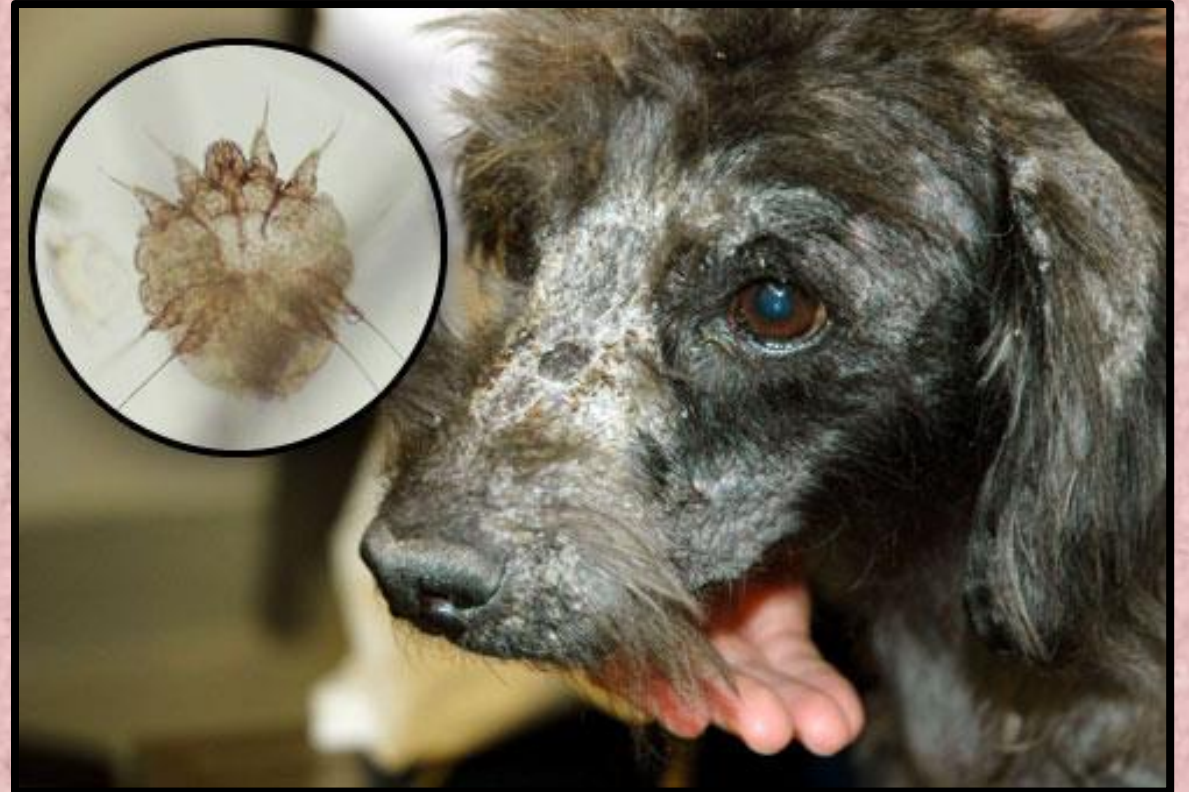Immune deficient animals , prolonged half treated dermatitis

Malassezia dermatitis - Treatment

- ❖ Similar to anti fungal treatment
- ❖ Prolonged even upto 6 months
- ❖ Ketaconazole – drug of choice
- ❖ Amitraz – may be needed
 - 1ml in 4ml of water
 - after bath with ketoconazole
- ❖ Liver protectants - essential

External parasites

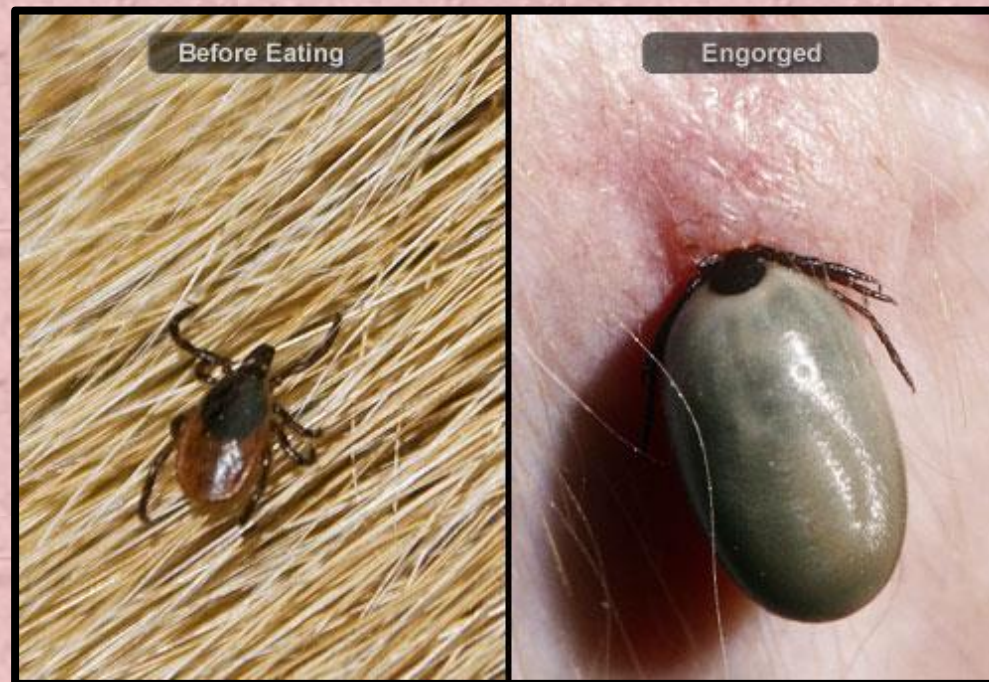- Ticks, Fleas, Mange (Demodex, Sarcoptes, Psoroptes)
- Prior to monsoon
- Alopecia
- Itching, oozing
- Scabs Crusts formation
- Excoriations
- Irritable, Snappy behavior
- Dull
- Maggot wounds – secondary
- Bacterial infection – secondary
- Surroundings affected – Vicious cycle



Fleas



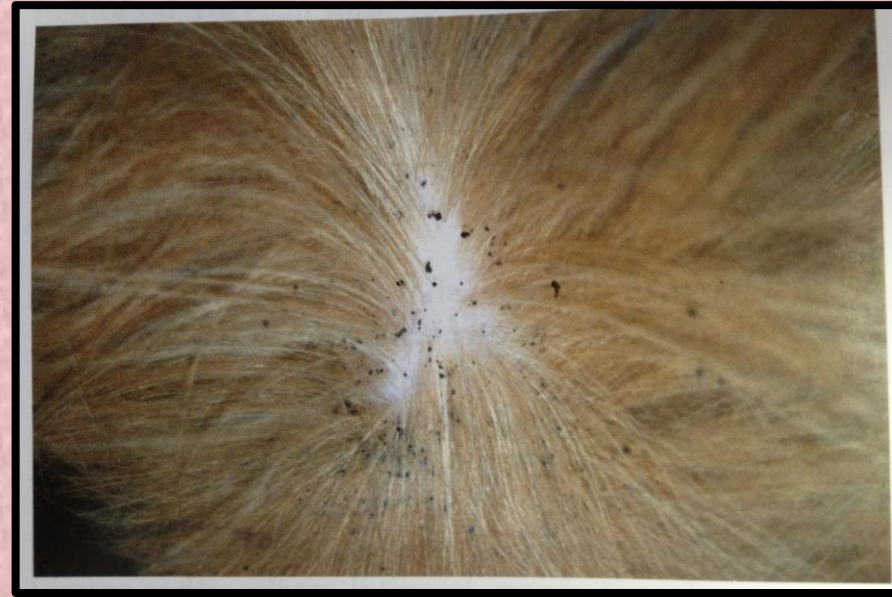Ticks





Flea infestation - diagnosis

Symptoms :

- ❖ Scratching behind the ear
- ❖ Rolling on its back
- ❖ Presence of flea dirt on back line, croup



External parasites - Treatment

Principle : Clean dirt  apply medication  deal with surrounding **BODY**

- Shampoos : permethrin, cypermethrin
- Sprays : Fipronil with or without S- Methoprene (weekly).....
- Spot on : Fipronil, S- Methoprene, Selamectin, Imidacloprid.... (weekly)
- Oral : Ivermectin 200mcg/kg body wt
- Parenteral : Ivermectin(SQ) , Doramectin(IM)

SURROUNDINGS

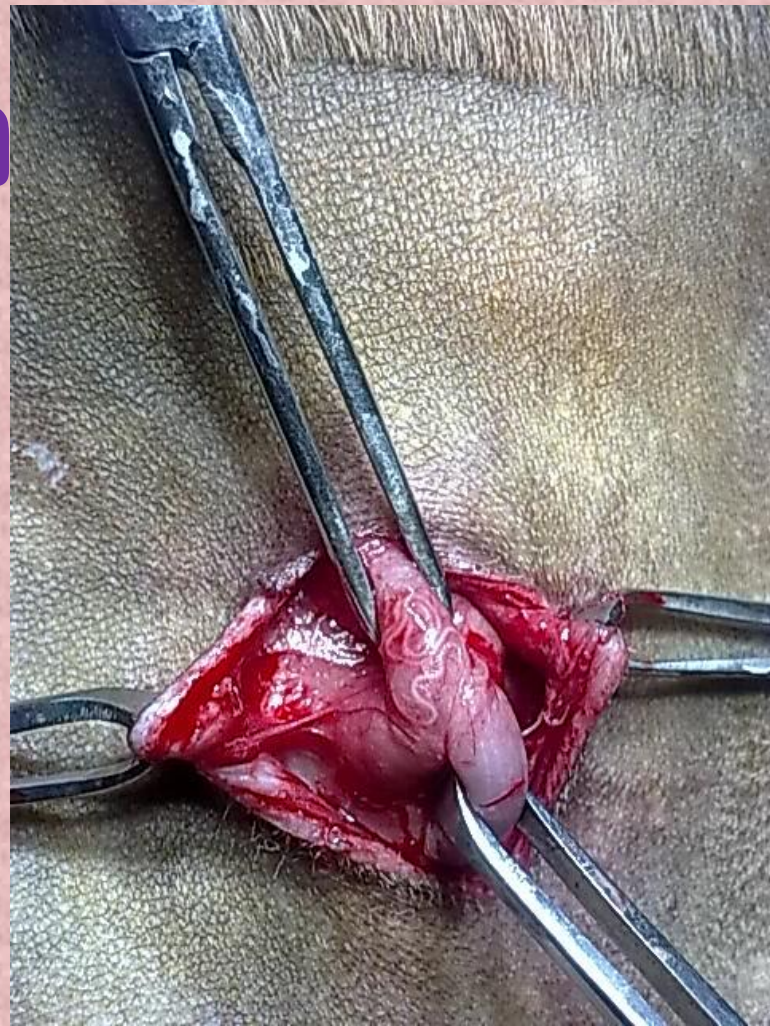
- Clean with cloth detergent
- Amitraz 12% - RIDD, Amitick (1ml : 2ml water)
- Use fire to touch all areas (does not enter crevices and fissure)

Internal Parasites

- **Microfilaria**
- **Erlischia**
- **Babesia**
- **Anaplasma**
- **Leishmania etc etc**
- **List goes on!**

Microfilaria/ Heart worm

- ❖ **Dirofilaria immitis etc**
- ❖ **Filarial worms**
- ❖ **Microfilaria in blood, plasma**
- ❖ **Later can block terminal vessels**
- ❖ **Lodges in aorta**
- ❖ **Can cause cardiac arrest**



Microfilaria/ Heart worm

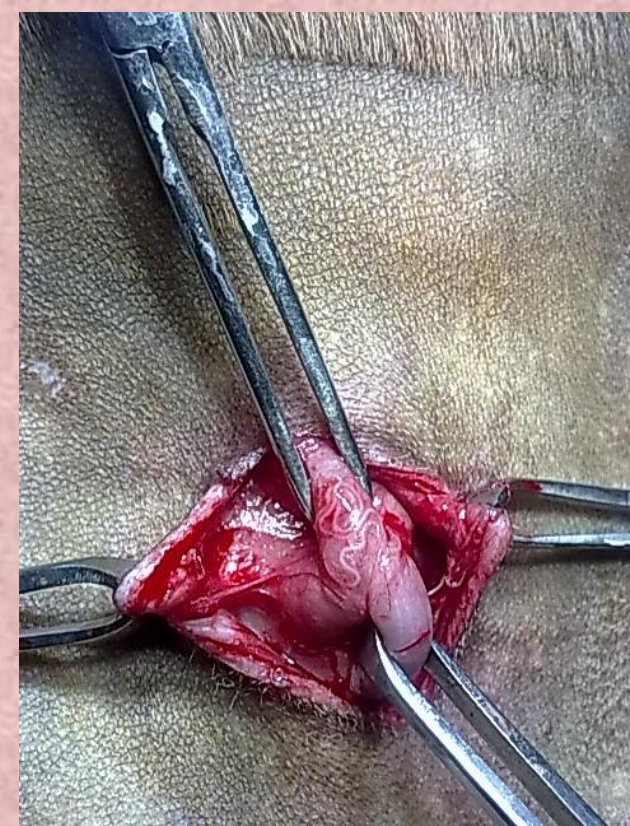
SYMPTOMS:

- ❑ Inter digital erythema
- ❑ Itching, oozing
- ❑ Fissures on dorsal aspect
- ❑ Hot spots (secondary bacterial infection)

DIAGNOSIS & TREATMENT :

Wet film

- ❖ <2/hpf – ivermectin @ 200mcg/kg b wt SQ (repeat after 1week)
- ❖ 2 - 4/ Hpf – Ivermectin @ 1/4th dose SQ (Full dose @ weekly interval)
- ❖ > 4 / Hpf - Diethylcarbazine Citrate (Banocide @ 10mg /kg oral)
- ❖ - W/F biweekly ..till load come to <2/Hpf



Microfilaria/ Heart worm

PREVENTION:

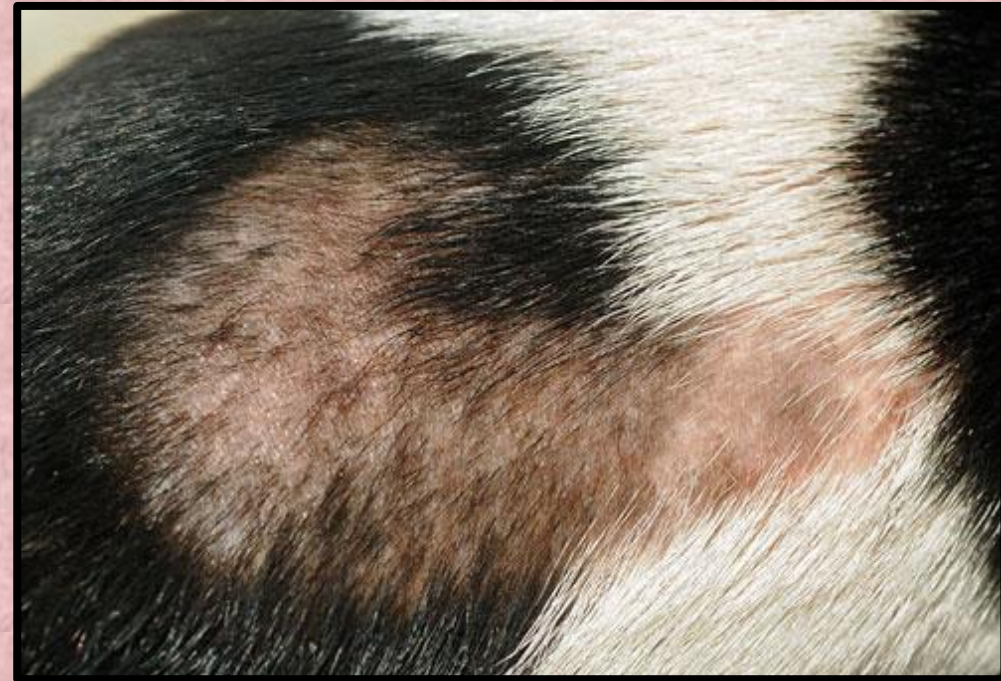- - W/F every 3 months
- - Selamectin spot on (Selamec, Revolution, Radicate)
- <10Kg/ 10 -20Kg/ 20-40 Kg/ 40 -60Kg

Dry Skin

- *Diet*
- *Excess use of Shampoo*
- *Environment*

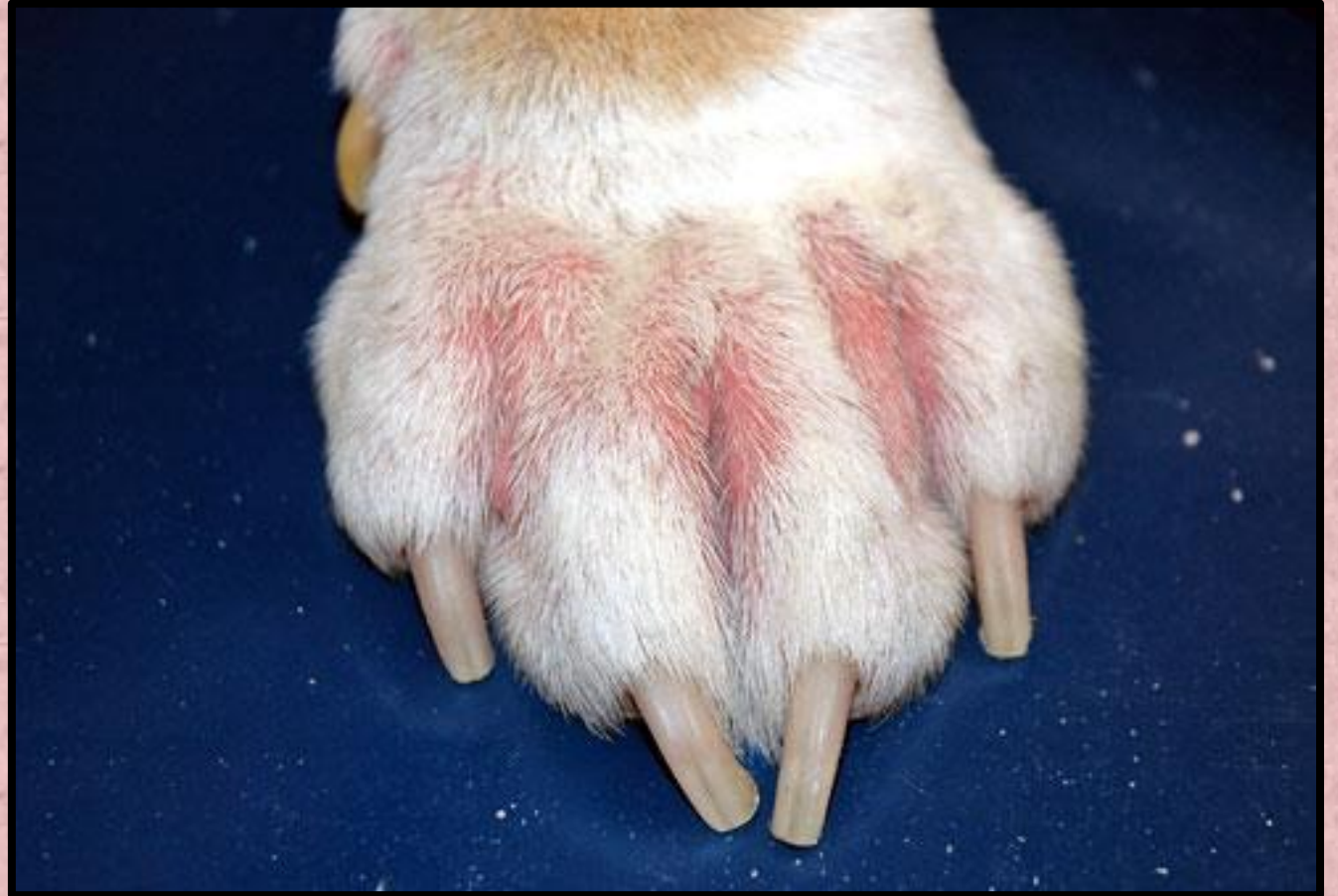TREATMENT :

- Correct diet and environment
- Supplements
- Oiling : Neem oil, Flematic skin oil (Ttk), normal oils
- Correct shampoo bath:
 - ✓ Do not leave the shampoo on for 10 – 20 mins
 - ✓ Keep massaging the body with shampoo on
 - ✓ Wash off after 5 -10 mins massage



Allergic dermatitis

- Atopic dermatitis
- Contact with allergens
 - skin
 - air
 - food
- Locate allergen
- Recurrence



Allergic / Atopic dermatitis

❖ Find the Allergen

❖ Treat for local symptoms

Hypertonic dip/wash + local ointments daily basis(Ichmune c)

Bathing : Soothing agents like piroctone olamine (Virbac, Vivaldis)

❖ Cyclosporine (eg Ichmune T capsules 25mg/50mg)

Dose : 3 -6 mg/ kg body wt upto 10 mg /kg in severe cases

Immunosuppressant

Side effects : Vomiting, diarrhoea, anorexia, otitis externa, bacterial dermatitis, fungal dermatitis, cystitis, urethritis, lowered immunity

❖ Antihistamines

❖ Other symptomatic treatments

Hormonal problems

- Hypothyroidism
- Hyperthyroidism
- Cushing's syndrome (Excess cortisol- ACTH)(Pituitary dysfunction)
- Addison's disease (hypocortisolism)(Adrenal dysfunction)
- Diabetes
- List goes on....

Do's & Don'ts in skin infections

- Refrain from steroids
 - ✓ Single use , 1 week, taper and stop
 - ✓ Immunosuppressant, leading to complications in long run
- Correct diet and environment
- Correct bathing method and interval
- local ointments till fur grows to normal (difficult in chronic cases)
- Don't change shampoos
- Immune boosters like Immunol – after other treatment
- Continue Skin tonics
- Coach client for early symptoms
- Reinfection

