




Respiratory

Dr. Ed Neufeld B.A. M.Div. D.V.M.

Chief Complaint

- “Coco”
- 5 year old spayed DSH cat
- Overweight
- Chronic Cough for the past 4 weeks
- Sometimes has labored breathing or wheezing

Coco



History

- Good appetite
- Chronic dry cough for the past 4 weeks
- Often found retching after drinking water
- Exercise intolerance
- Panting periodically especially when stressed

Physical Examination

- Started to open mouth breath in the exam room
- Temperature 38.0 degrees C
- Heart Rate 200 bpm
- Respiratory Rate 30 per minute.
- Expiratory dyspnea
- Chest auscultation – crackles/ expiratory wheezes

Problem List

- Coughing
- Mouth breathing/panting
- Pulmonary crackles
- Expiratory dyspnea

Rule Outs

- List of all the possible diagnoses
- This is your Rule Out List

Rule Outs

- Tracheal obstruction with a foreign body
- Feline Asthma, Bronchitis
- Pneumonia : FIP,
- Heart Disease : HCM, DCM
- Metastatic Neoplasia
- Lung Parasites

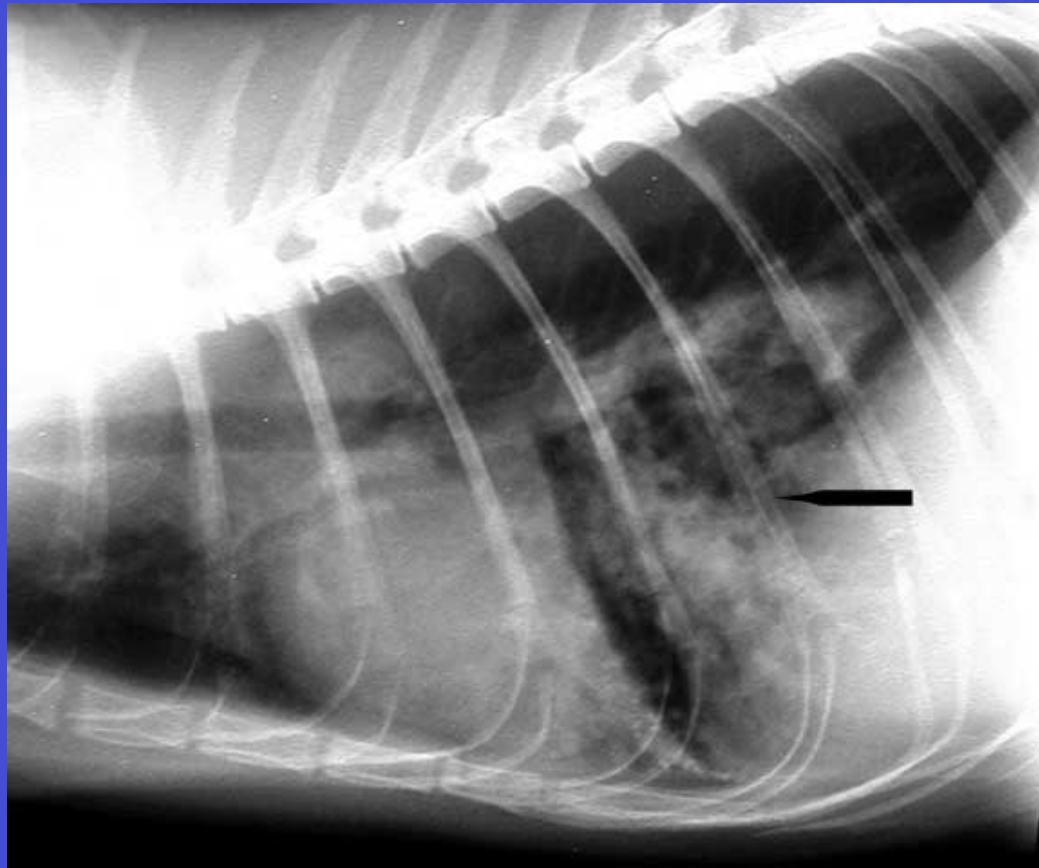
Plan

- Make a Plan – Diagnostic Tests
- List the Diagnostic Tests

Plan

- Thoracic Radiographs –
- Left lateral and V/D
- Fecal examination – check for lung worms

Left Lateral Thoracic Radiograph



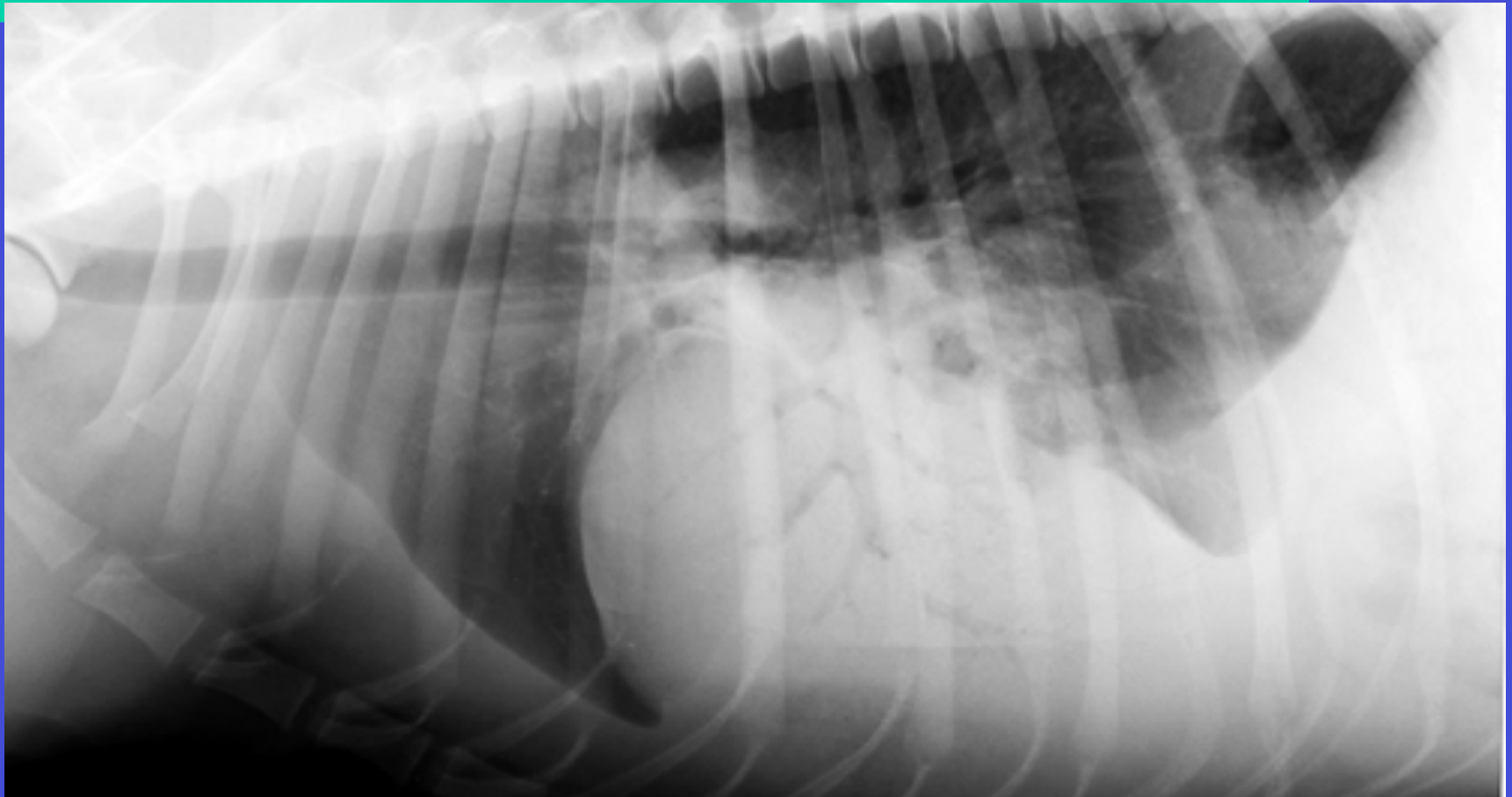
Thoracic Radiograph

-
- What radiographic lesions do you see?

Left Lateral Thoracic Radiograph

- Radiographic Findings
 - Thickened bronchial walls – doughnuts, in the caudal lung lobes
 - Bronchial pattern

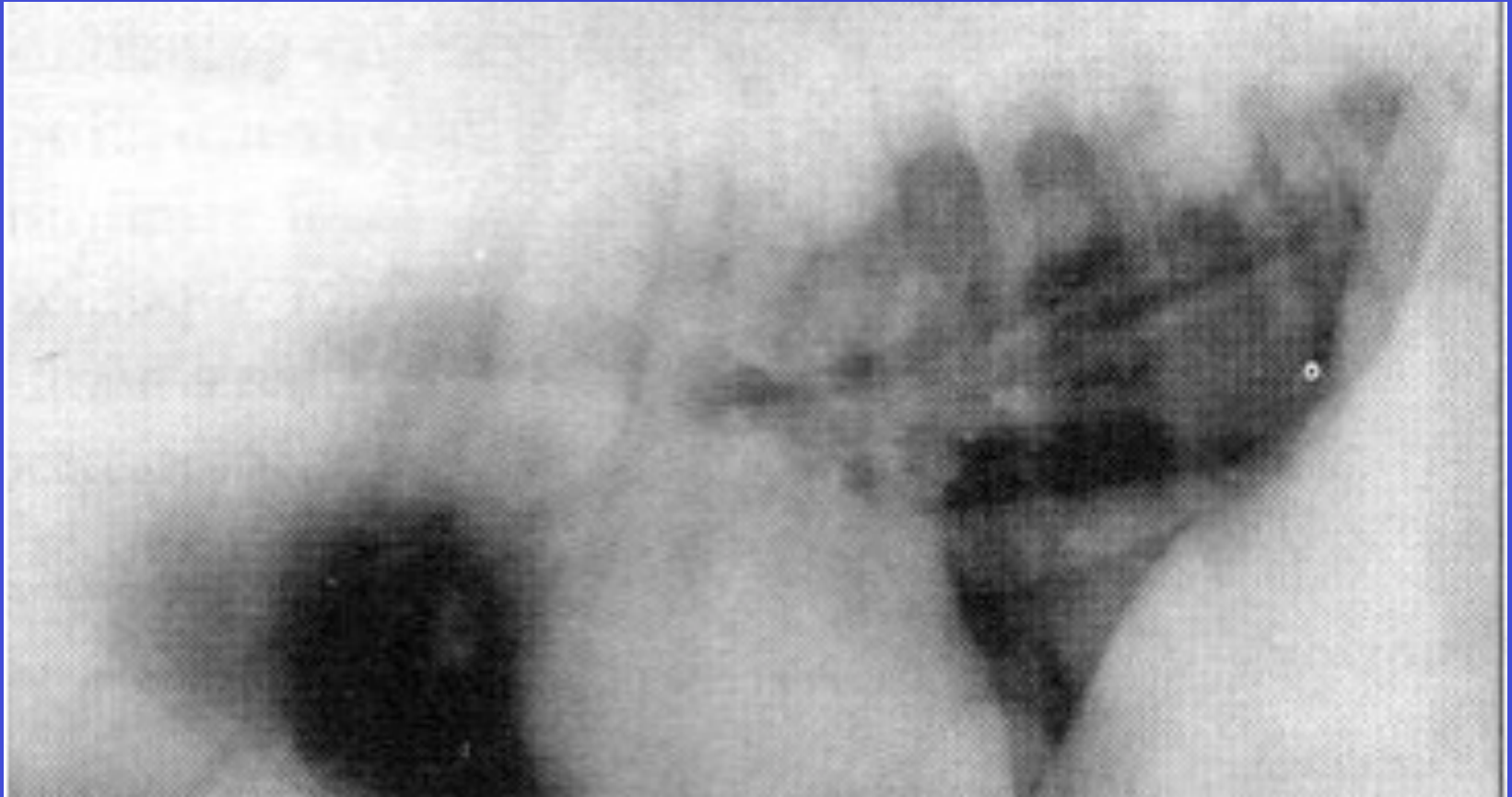
Alveolar Pattern – fluffy with no distinct borders



Alveolar Pattern

- Edema
- Hemorrhage
- Pneumonia

Interstitial Pattern



Interstitial Pattern

- Metastatic Nodules

Laboratory Findings

- Fecal examination – Negative

Assessment of the Plan

- Assessing :
 - Clinical signs, laboratory findings and radiographs

Mark each rule out as a likely or unlikely diagnosis

Diagnosis

- Tracheal foreign body – unlikely -negative on X-ray
- Feline Asthma, Bronchitis – very likely – coughing and “donuts” on radiograph.
- FIP –unlikely - no pleural effusion
- HCM, DCM –unlikely no pleural effusion and this cat is coughing – unusual for heart disease
- Lung neoplasia unlikely - no pulmonary nodules on X-ray
- Lung parasites – unlikely - negative fecal exam

Diagnosis

- Feline Asthma

What is your Treatment Plan?

- What is your treatment Plan?

Treatment Plan

- **Acute Care:**
- Hospitalize cat in acute crisis – Administer O2
- Sedation
- Injectable steroid/ Inhaled Steroids
- Inhaled Bronchodilators
- **Long Term Management – for life**
- Change the environment – no contact with smoke
- Oral Prednisone
- Depo Medrol

Inhaled Medications



Long term side affects of Feline Asthma and medications

- What are the long term side affect of Feline Asthma and the medications used to treat the disease?

Long Term Side Affects of Feline Asthma and Medications

- Long term steroids can result in Diabetes Mellitus therefore watch for signs of PU/PD
- Periodically measure blood glucose
- Right- side heart disease can develop from long term bronchitis

Prognosis

- What is the prognosis

Prognosis?

- Good for control of clinical signs
- Poor for complete cure
- Requires life long treatment for control



The End



